

Joint Examination and Injection Course

Mr Nadim Aslam
Consultant Orthopaedic Surgeon
Spire Bone and Joint Clinic

Worcestershire Knee and Hip Clinic

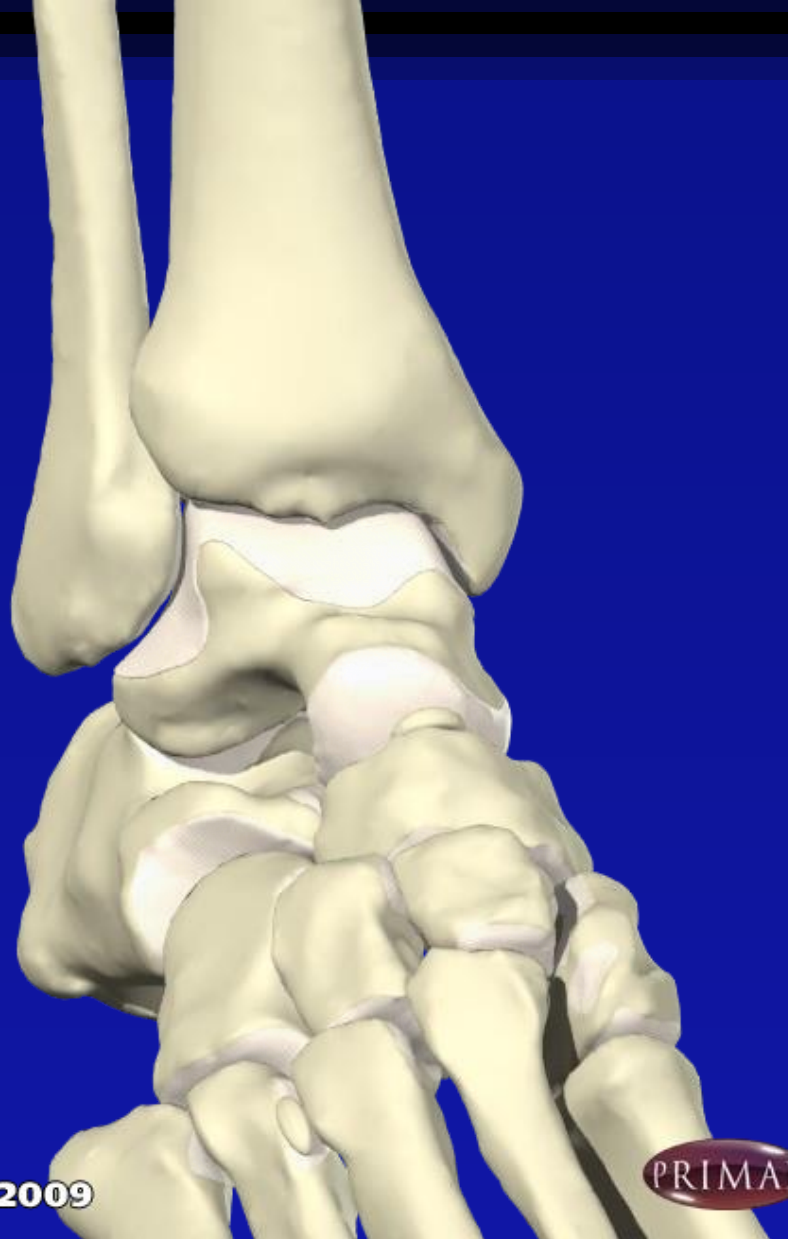
ANKLE JOINT

Ankle

- OA
- RA
- GOUT
- Other inflammatory arthropathies

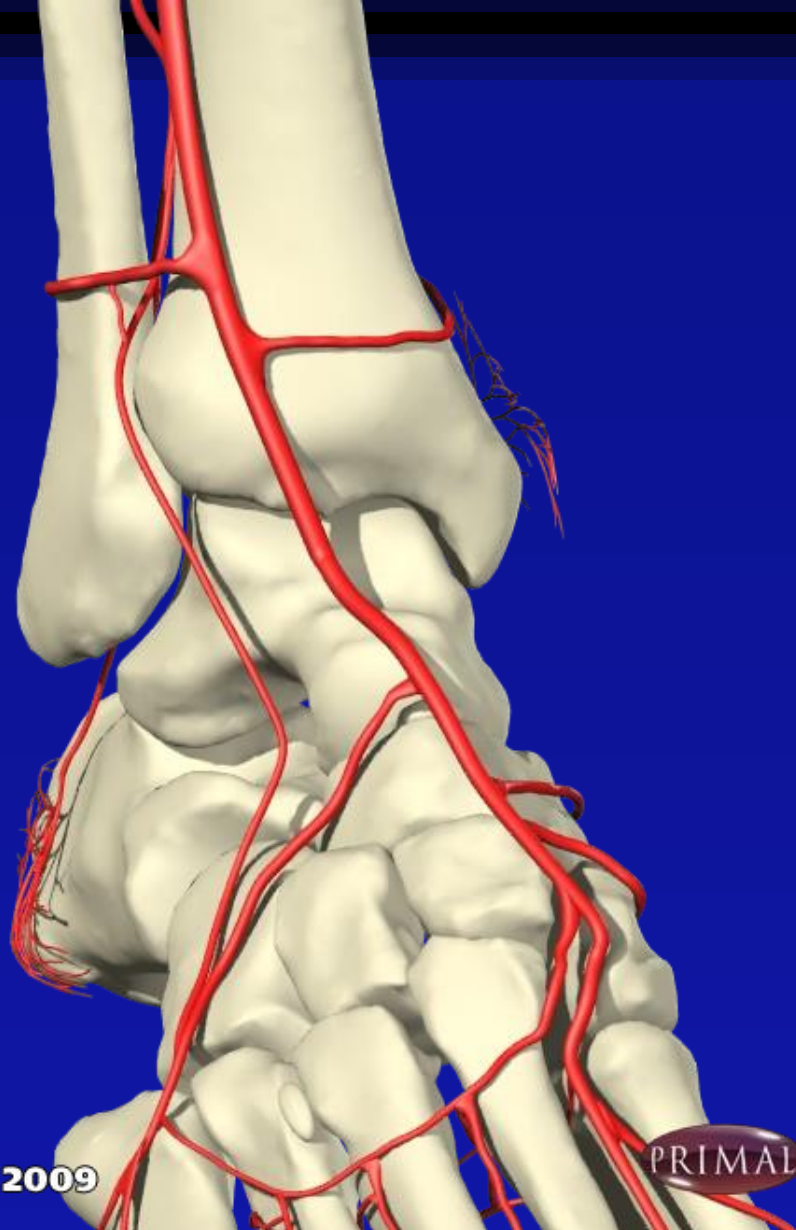Injection of ankle

- Just medial or lateral to extensor hallucis longus
- Dorsalis pedis artery lies just lateral to EHL
- Angle needle to run parallel to upper surface of talus or direct towards medial malleolus



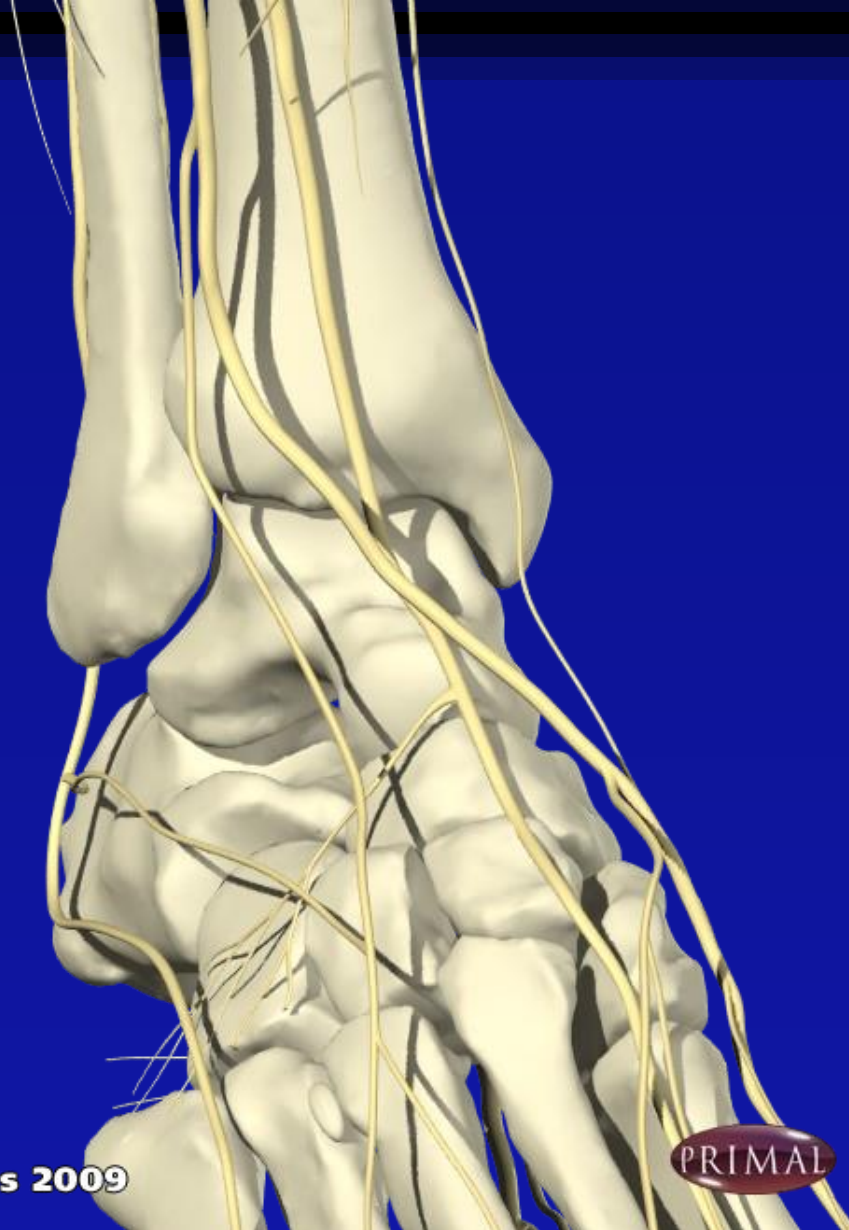
© Primal Pictures 2009





© Primal Pictures 2009

PRIMAL



© Primal Pictures 2009



Nadim Aslam
Consultant Sports and Reconstructive Knee and Hip Surgery

WxHC
Worcestershire Knee and Hip Clinic

Achilles Tendonitis

- Inflammation of tendon and its insertion
- Can be associated with AS and Reiters or occur on its own
- Diffuse inflammation not amendable to injection (also risk of rupture)
- Treat with heel pad and stretching

Joint Examination and Injection Course

Mr Nadim Aslam
Consultant Orthopaedic Surgeon
Spire Bone and Joint Clinic

Worcestershire Knee and Hip Clinic

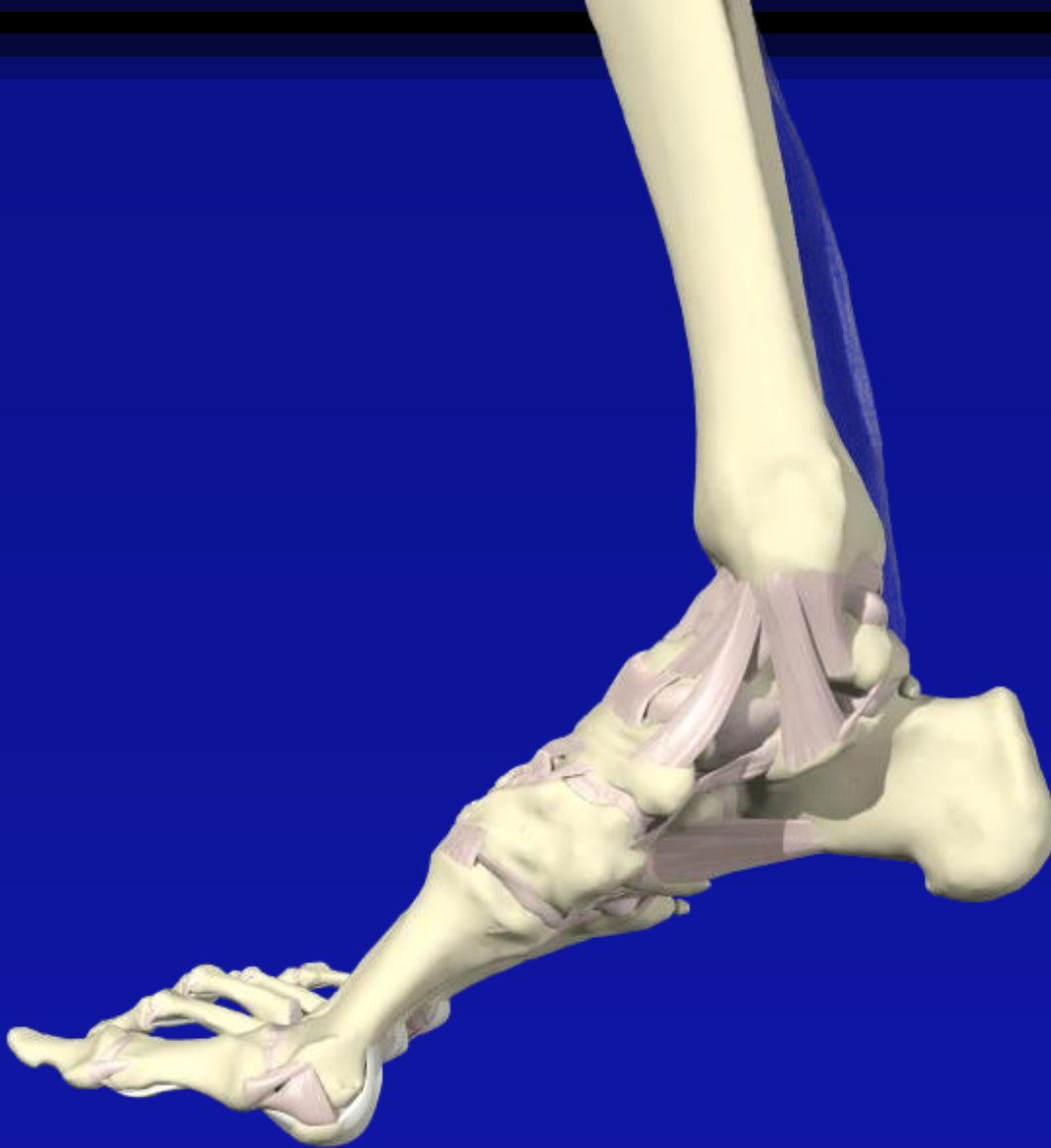PLANTAR FASCITIS

Plantar Fasciitis

- Pain under heel on WB
- Pain worse getting out of bed or after inactivity
- Pain can extend along medial foot
- May or may not have spur, not the cause. Xray does not change management
- Treatment:
- Lose weight
- Gel heel pads/ Arch support
- Injection if mobility impaired

Injection of Plantar Fasciitis

- Pain under heel
- Medial approach less painful
- 40 mg Depomedrone/ lidocaine mix by medial approach

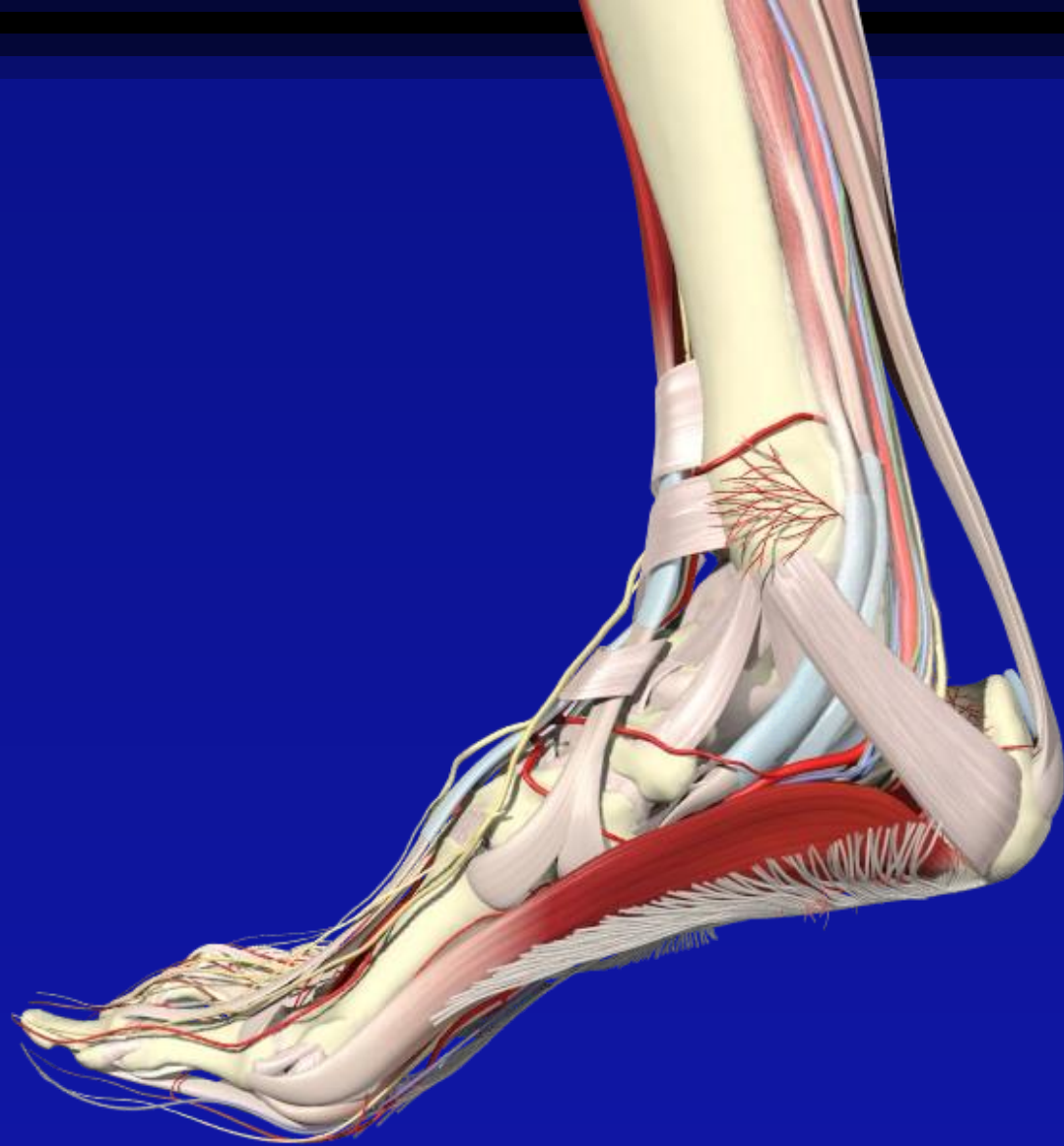


© Primal Pictures 2009



Nadim Aslam
Consultant Sports and Reconstructive Knee and Hip Surgery





© Primal Pictures 2009



Nadim Aslam
Consultant Sports and Reconstructive Knee and Hip Surgery

WxHC
Worcestershire Knee and Hip Clinic

THE END