

Joint Examination and Injection Course

Mr Nadim Aslam
Consultant Orthopaedic Surgeon
Spire Bone and Joint Clinic

Worcestershire Knee and Hip Clinic

DIAGNOSING AND MANAGING LOWER LIMB CONDITIONS

Hip

Knee

Ankle

Foot



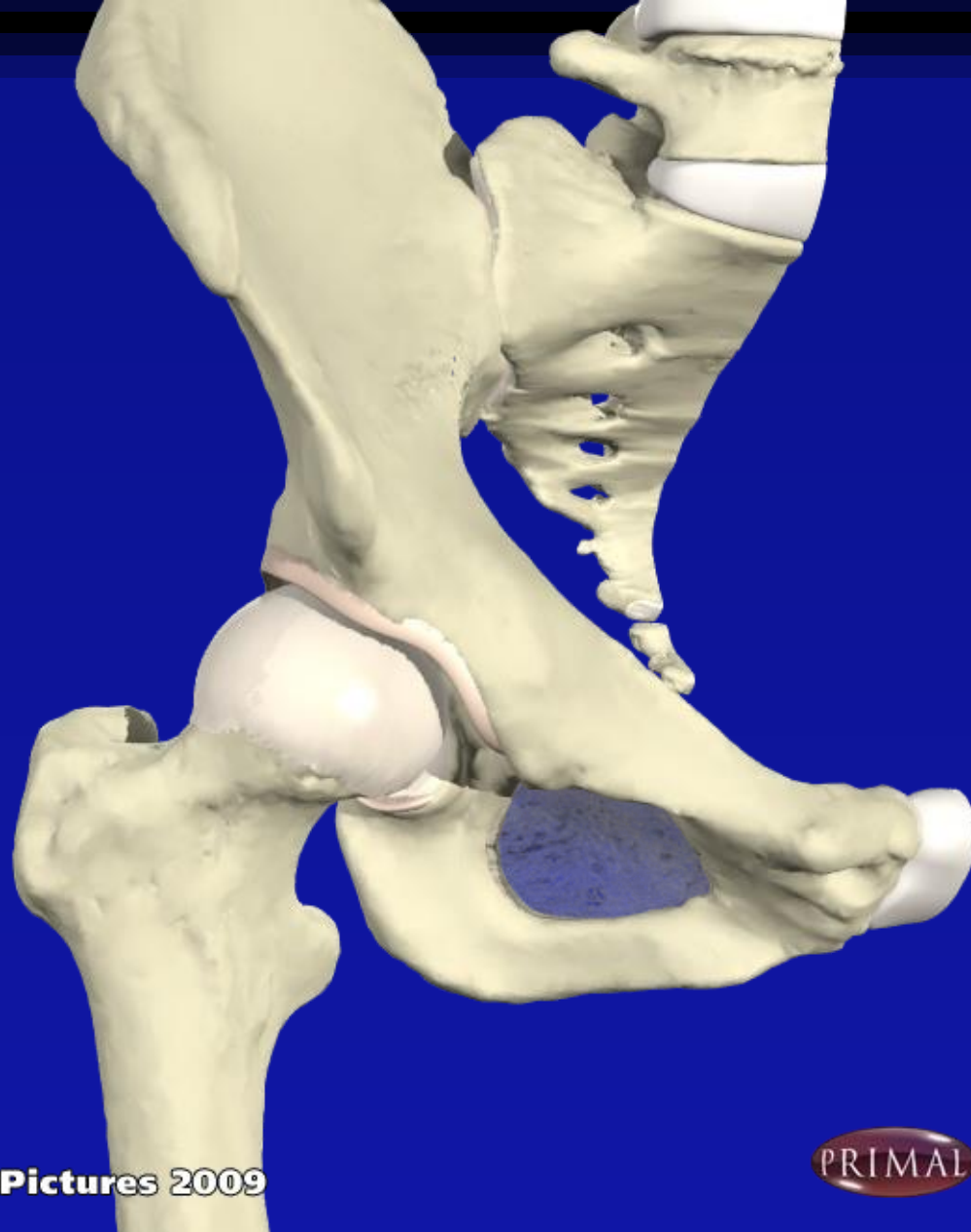WHAT IS THIS CLINICAL SIGN?



Greater Trochanteric Pain Syndrome (Bursitis)

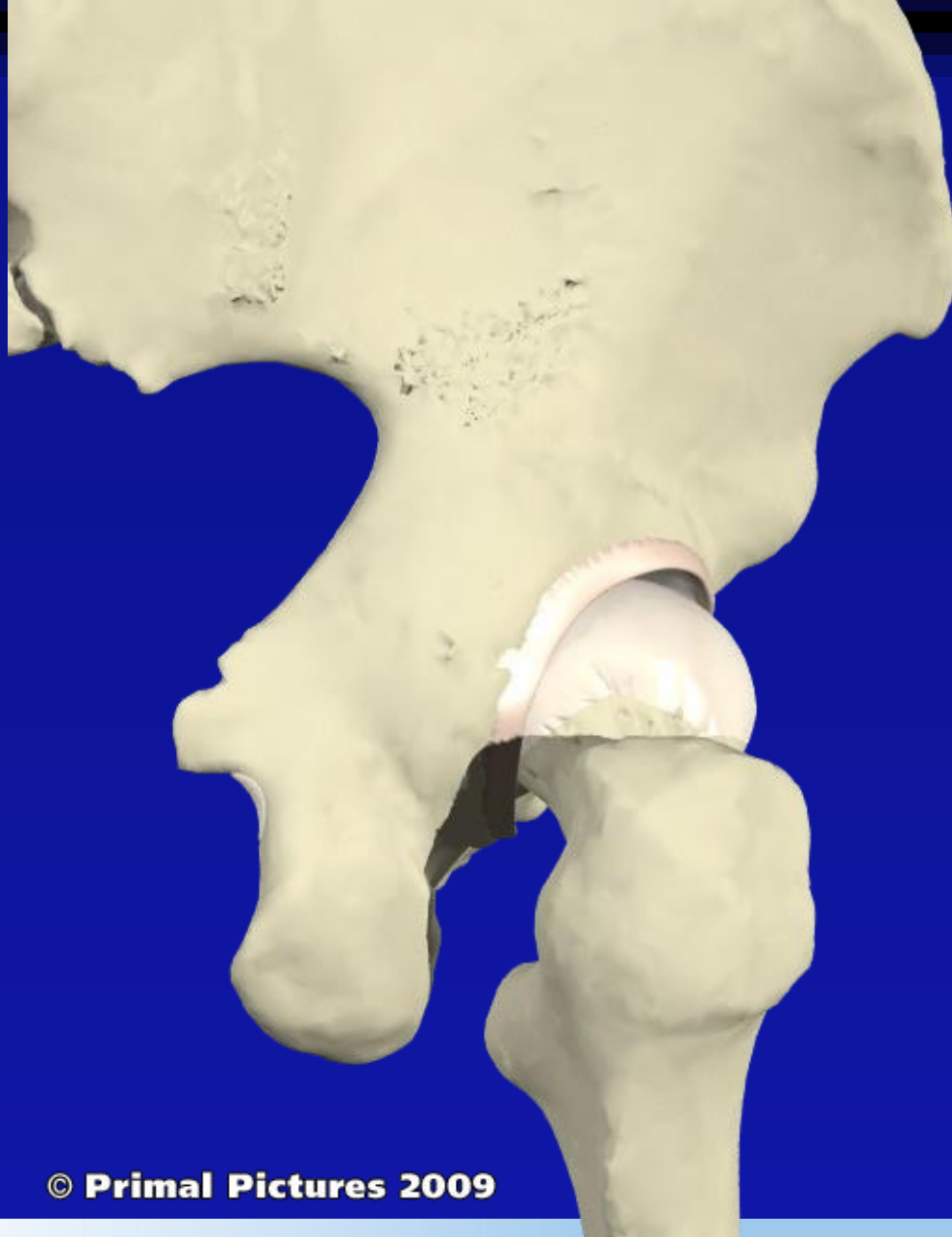- Pain over GT especially with weight bearing
- Unable to lie on affected side
- Usually over-weight
- May have short leg causing pelvic tilt (needs correction with shoe raise)
- Pain on resisted abduction

Hip



© Primal Pictures 2009



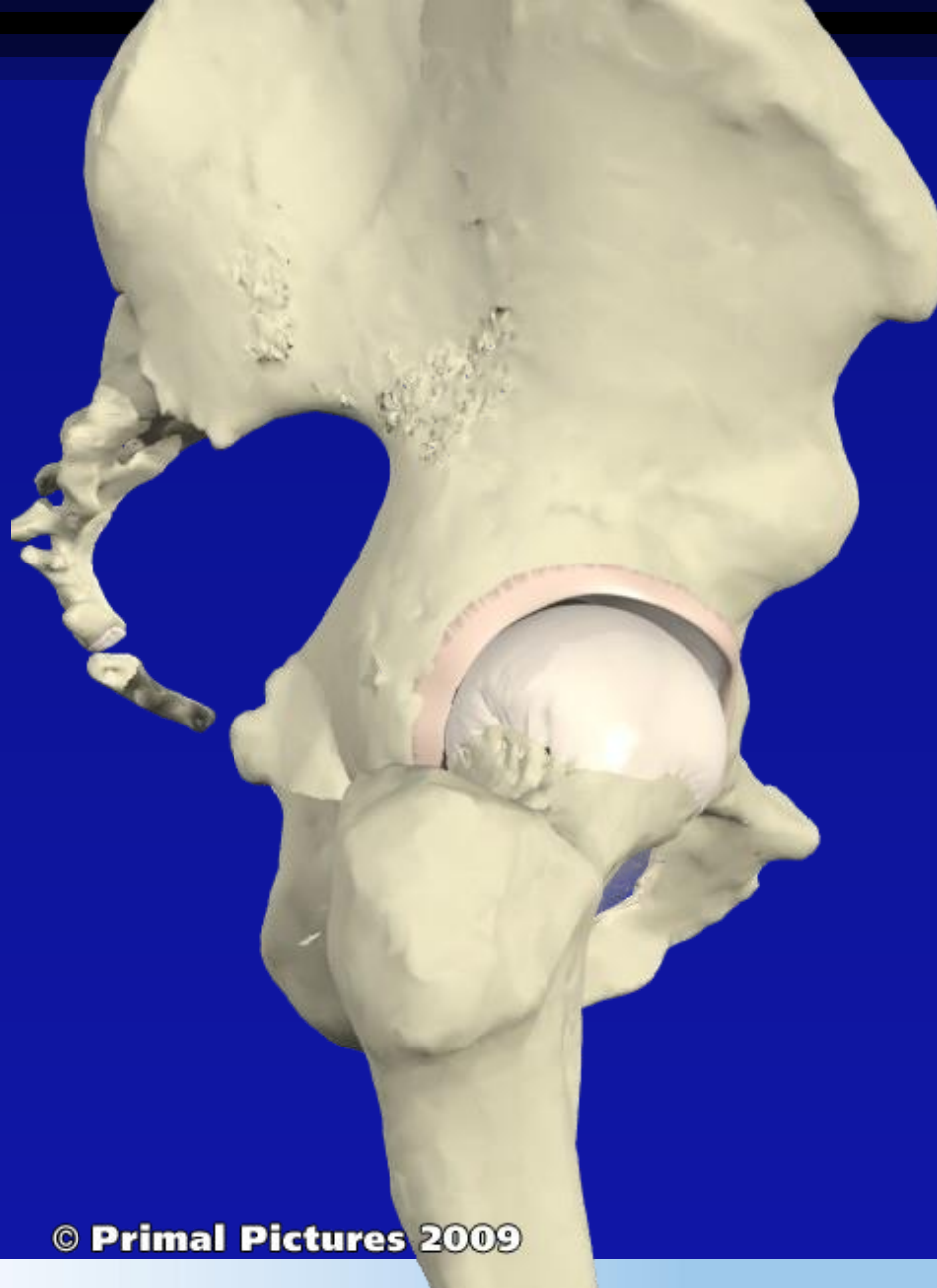


© Primal Pictures 2009



Nadim Aslam
Consultant Sports and Reconstructive Knee and Hip Surgery

WxHC
Worcestershire Knee and Hip Clinic

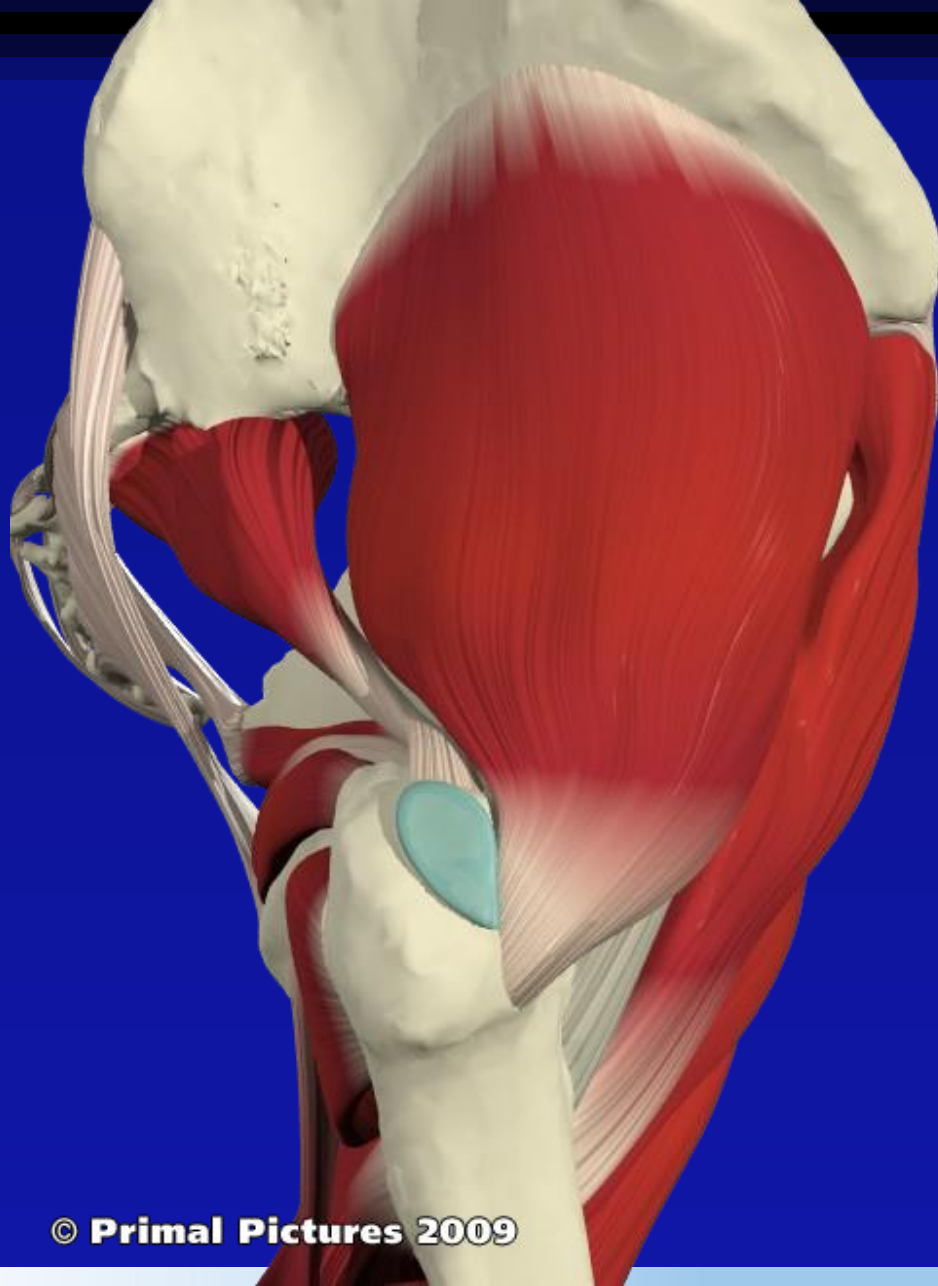


© Primal Pictures 2009



Nadim Aslam
Consultant Sports and Reconstructive Knee and Hip Surgery

WxHC
Worcestershire Knee and Hip Clinic

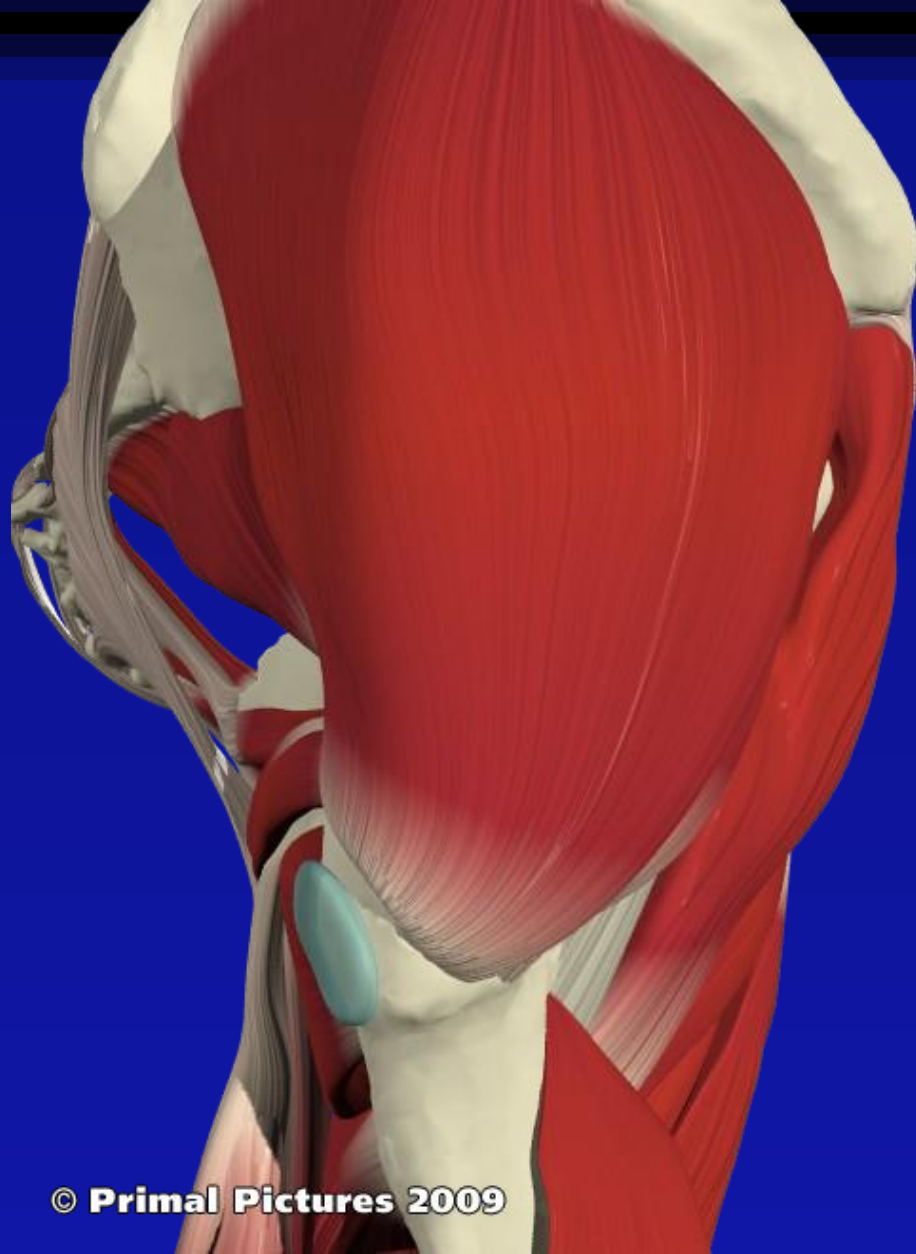


© Primal Pictures 2009



Nadim Aslam
Consultant Sports and Reconstructive Knee and Hip Surgery

WxHC
Worcestershire Knee and Hip Clinic

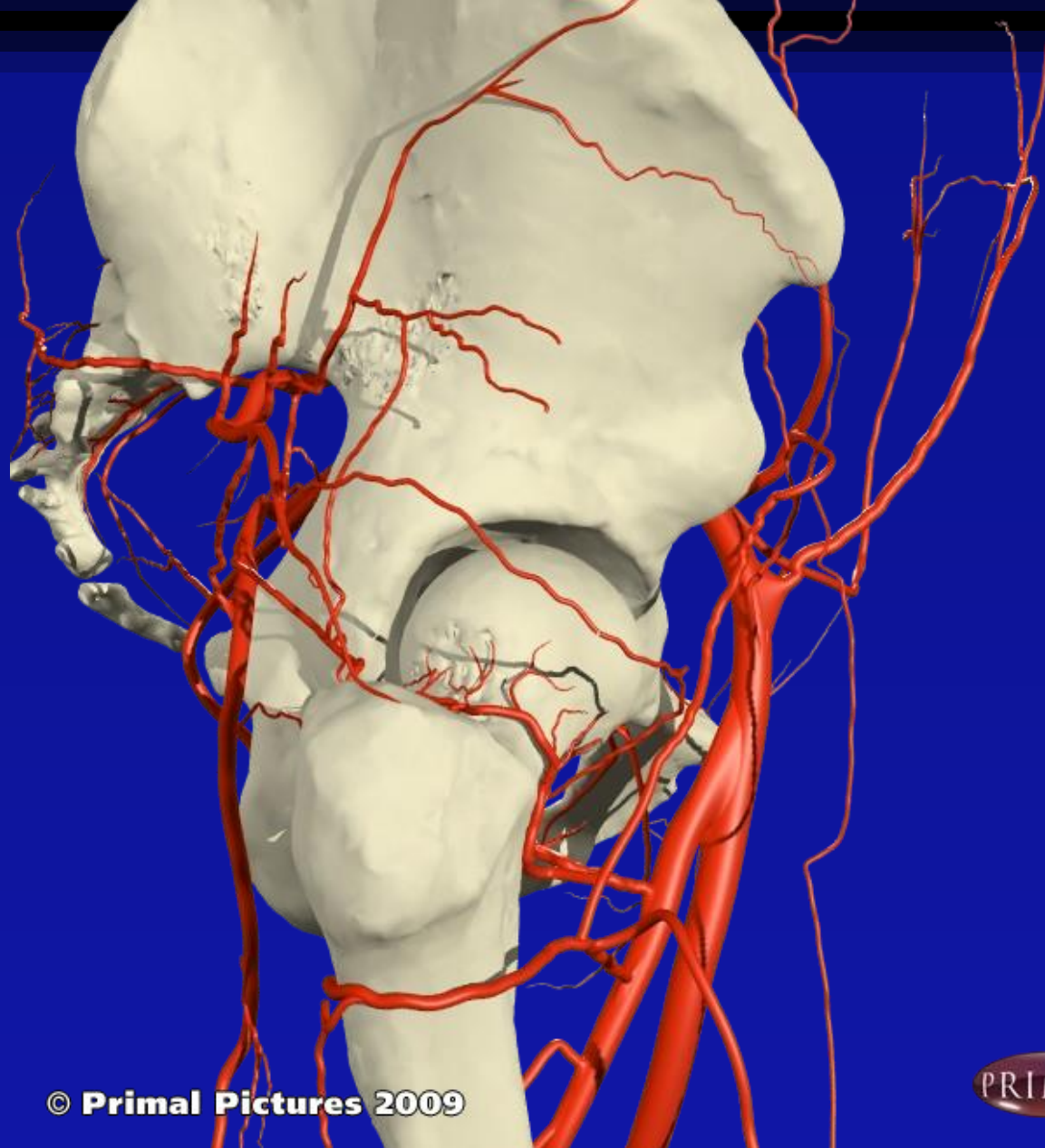


© Primal Pictures 2009



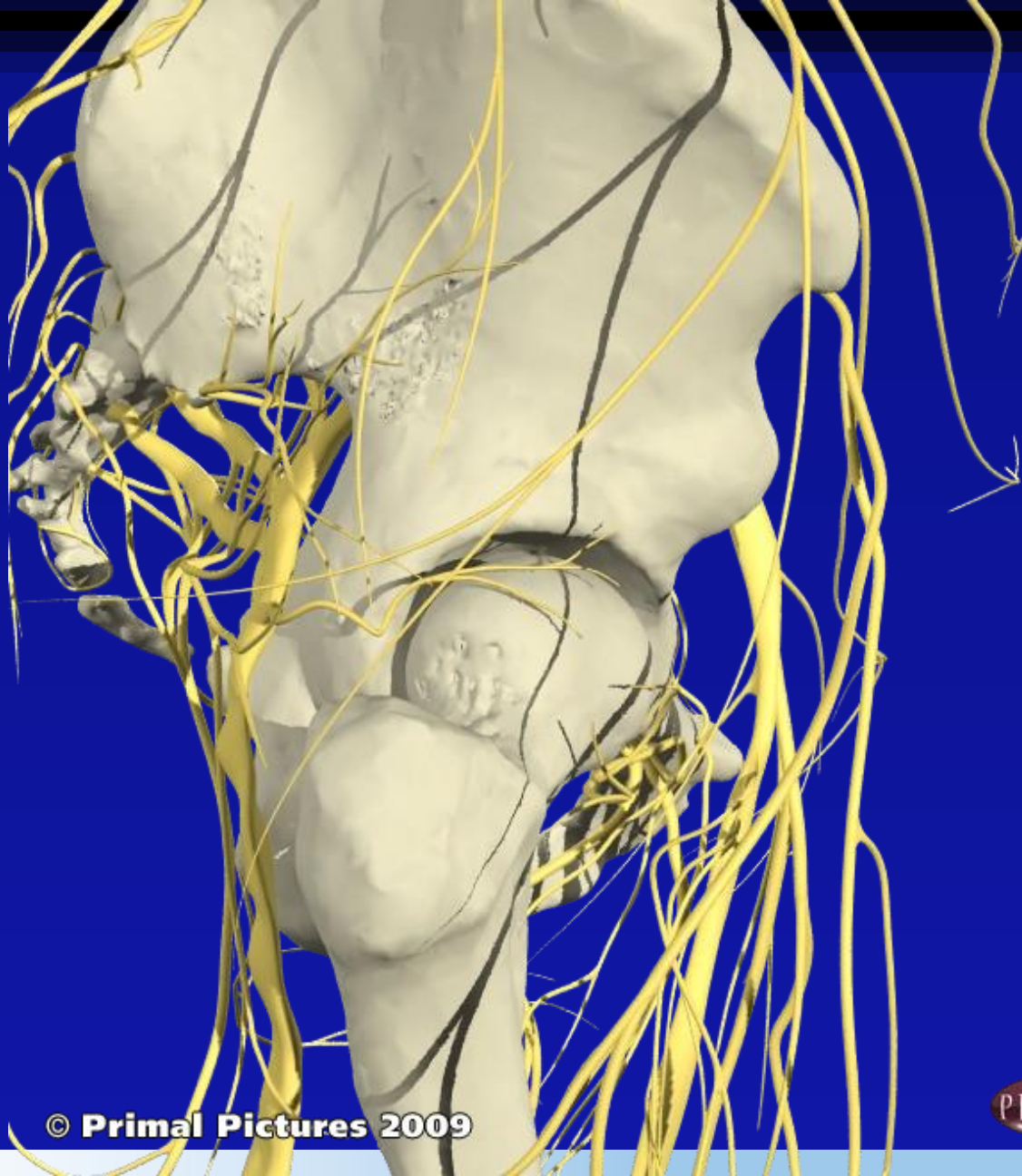
Nadim Aslam
Consultant Sports and Reconstructive Knee and Hip Surgery

WxHC
Worcestershire Knee and Hip Clinic



© Primal Pictures 2009



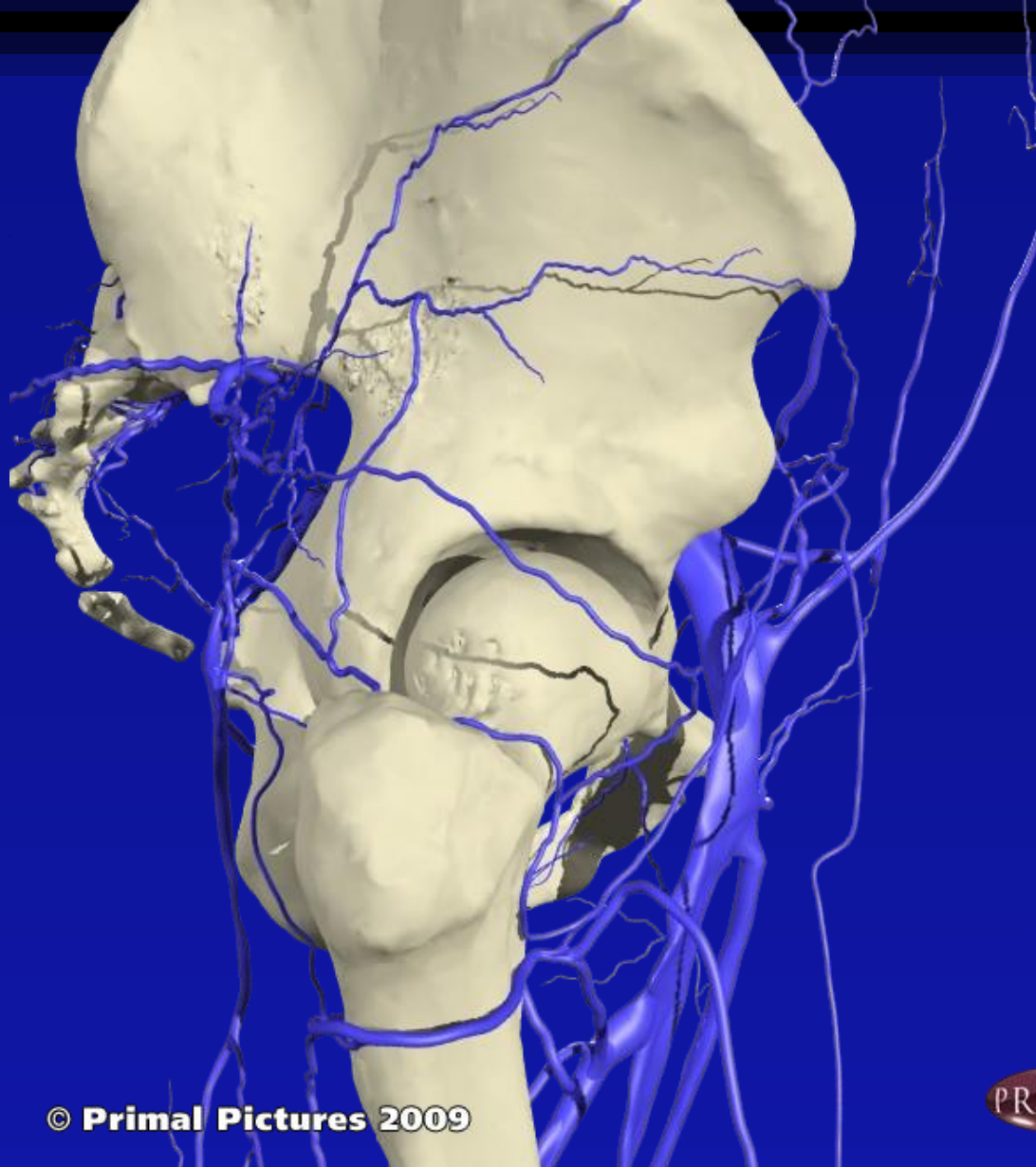


© Primal Pictures 2009



Nadim Aslam
Consultant Sports and Reconstructive Knee and Hip Surgery

WxHC
Worcestershire Knee and Hip Clinic



© Primal Pictures 2009

