

Joint Examination and Injection Course

Mr Nadim Aslam
Consultant Orthopaedic Surgeon
Spire Bone and Joint Clinic

Worcestershire Knee and Hip Clinic

DIAGNOSING AND MANAGING UPPER LIMB CONDITIONS

Shoulder

Elbow


Wrist

Hand



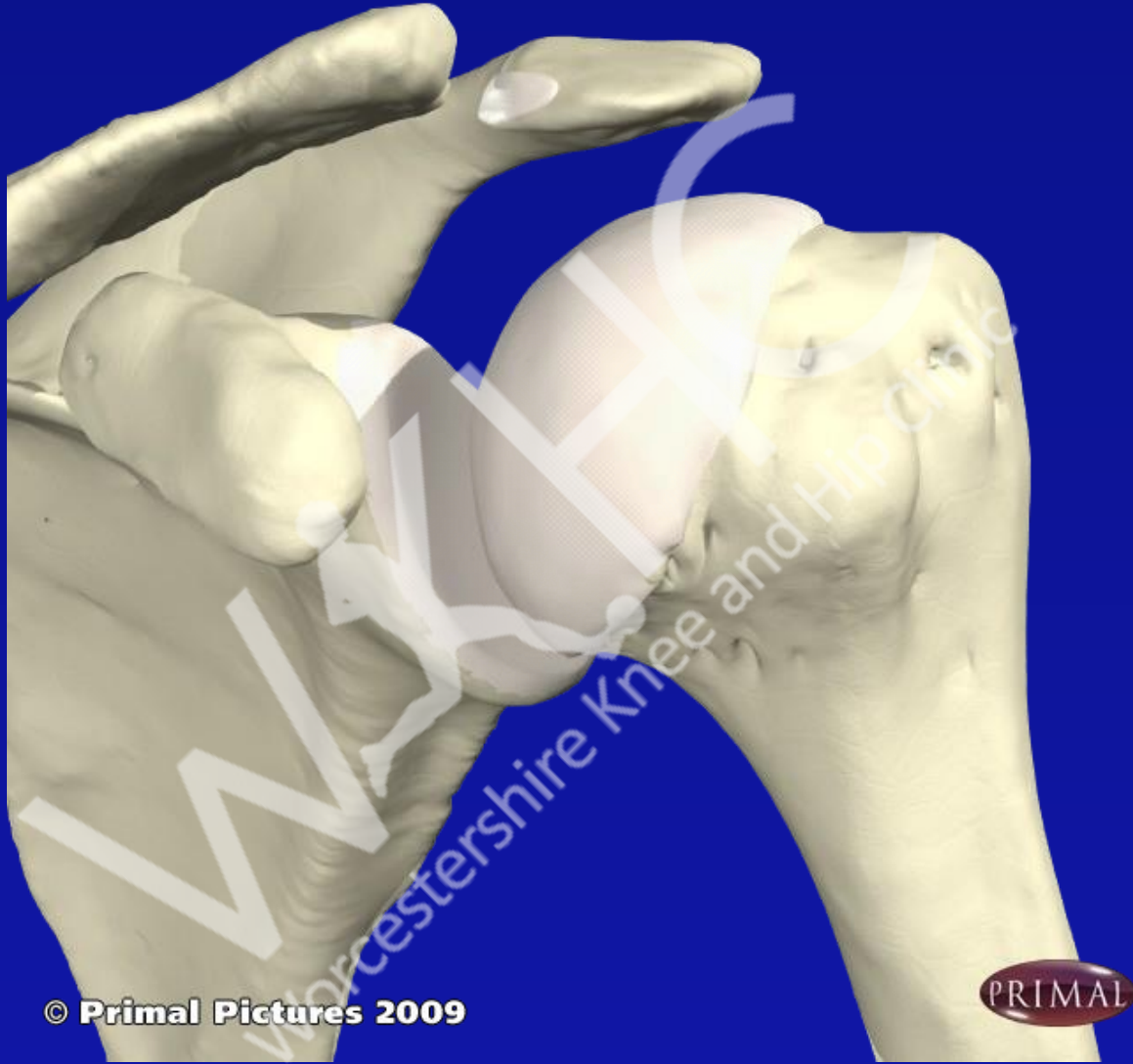SHOULDER AREA

- Acromioclavicular joint
- Adhesive capsulitis
- Rotator cuff (SITS)
- Supraspinatus
- Infraspinatus
- Teres minor
- Subscapularis

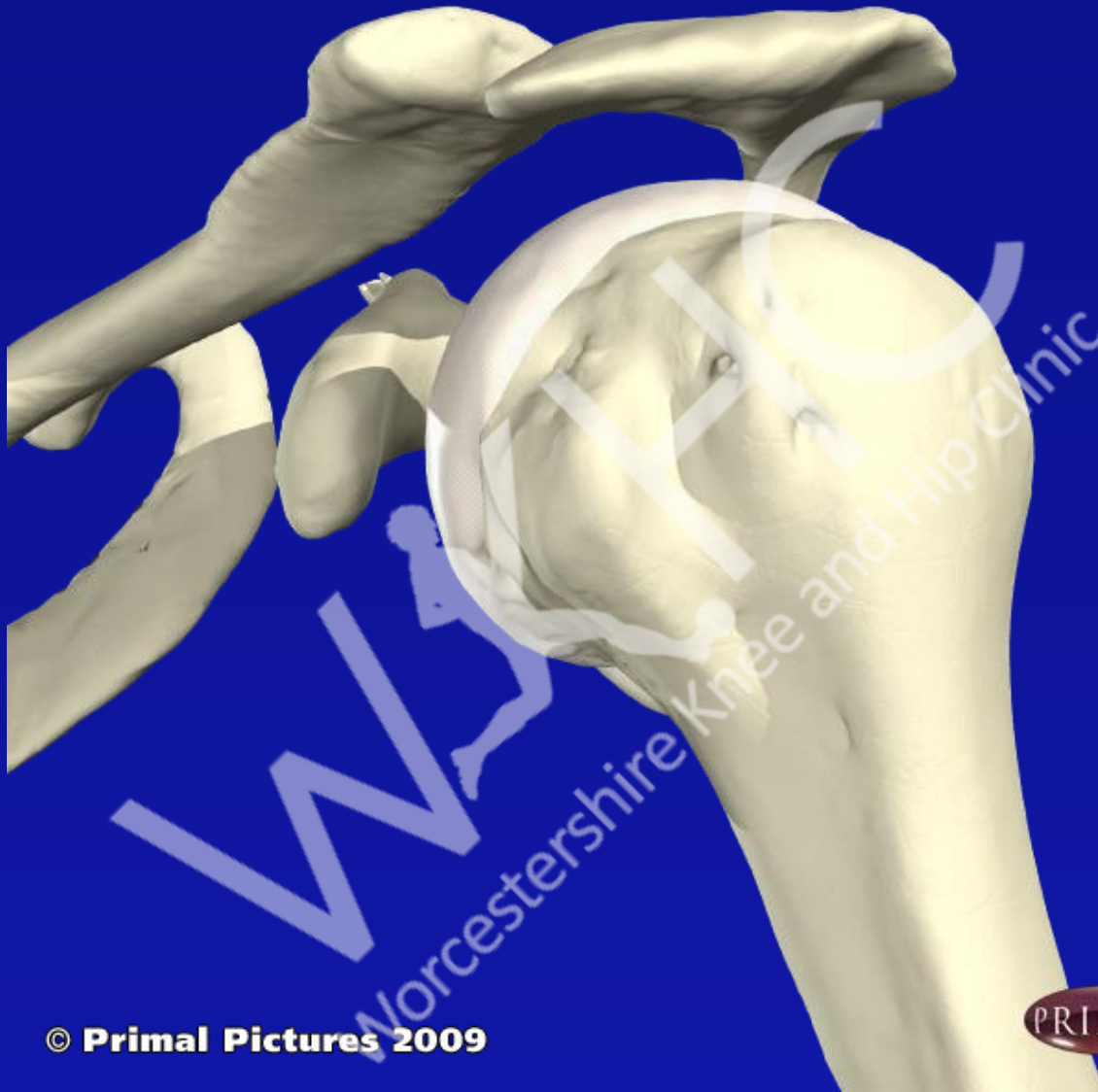

SHOULDER AREA

- Biceps tendonitis
- OA
- Pyrophosphate disease
- RA
- Other inflammatory arthropathies

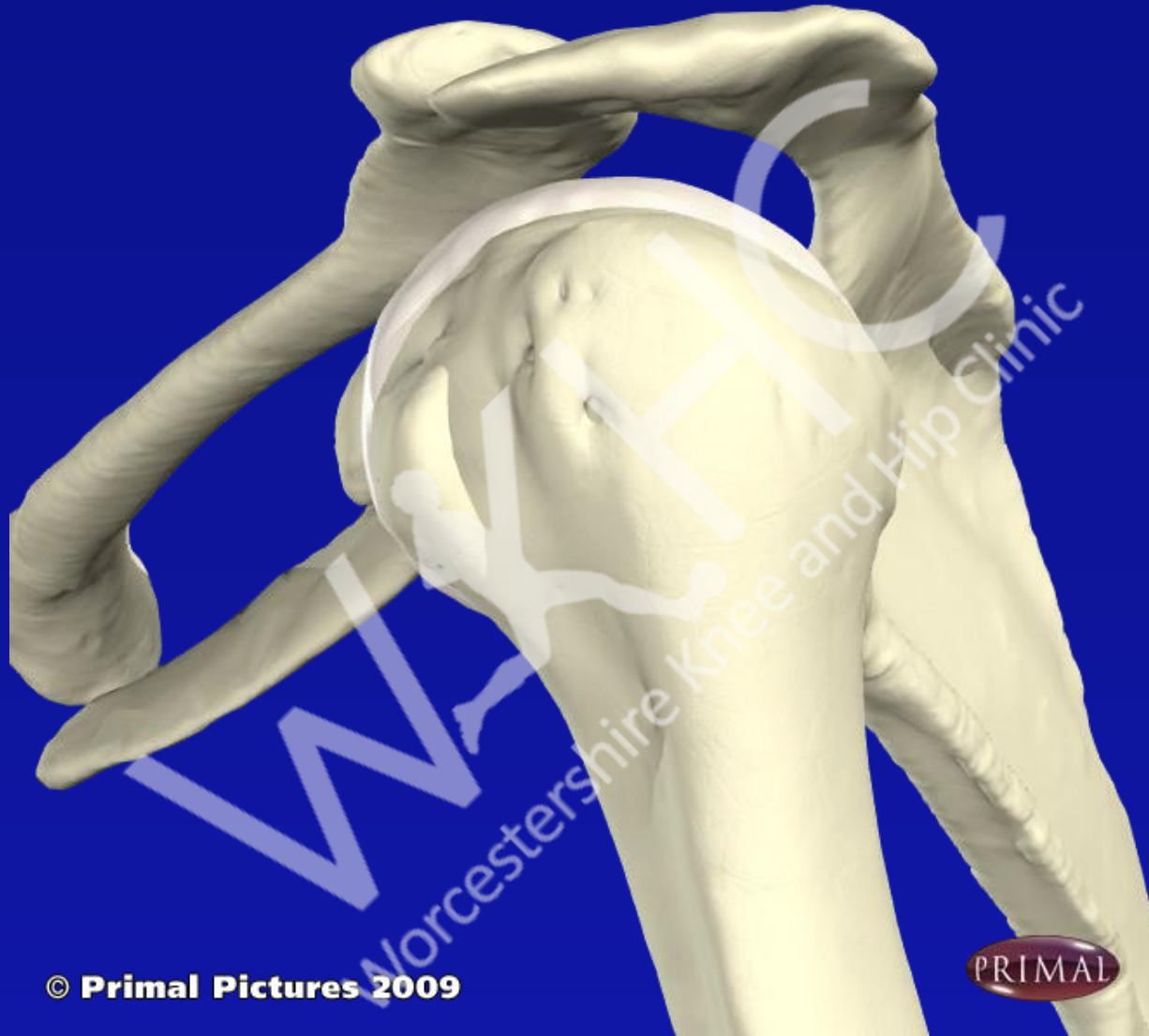


© Primal Pictures 2009

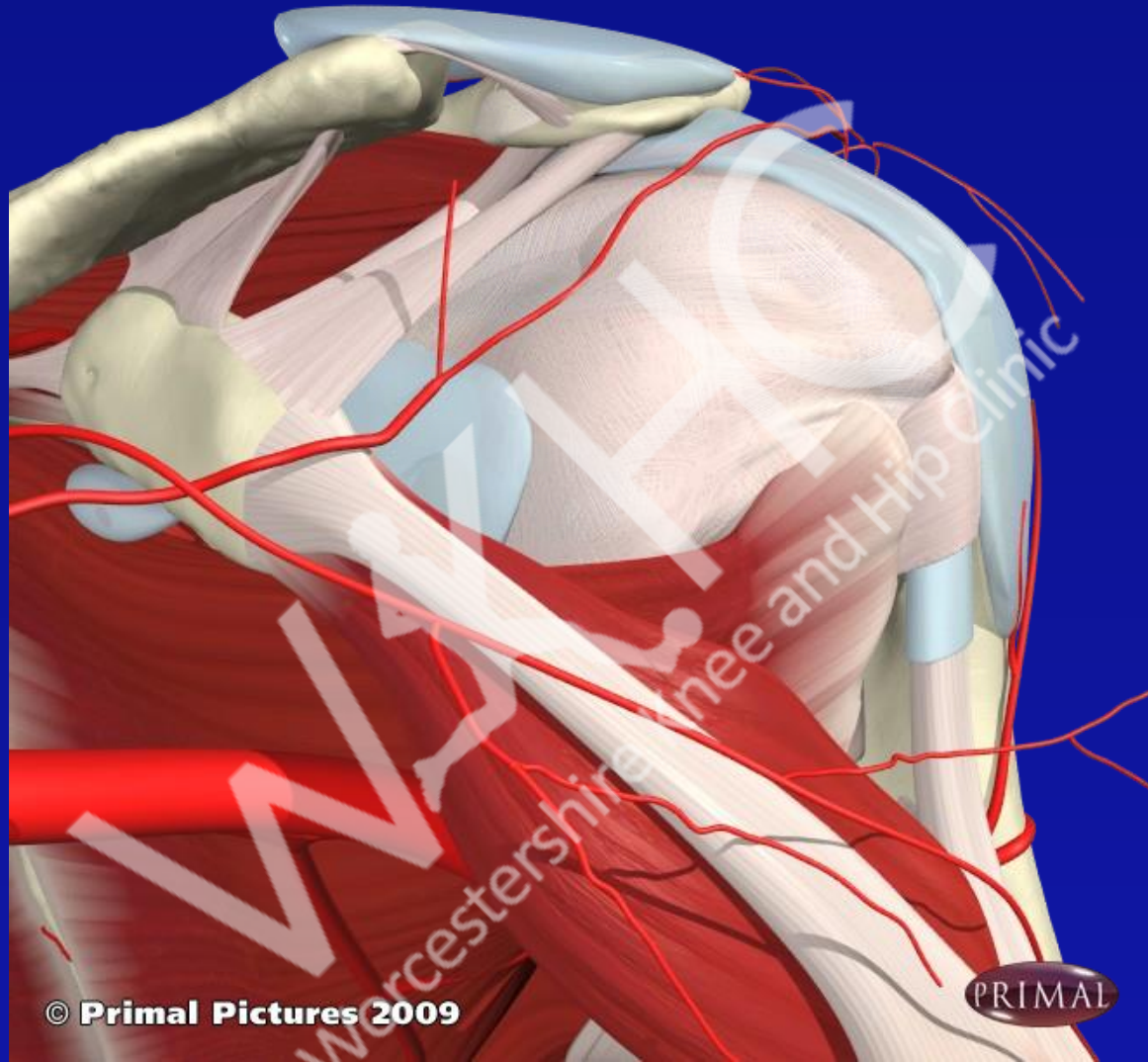


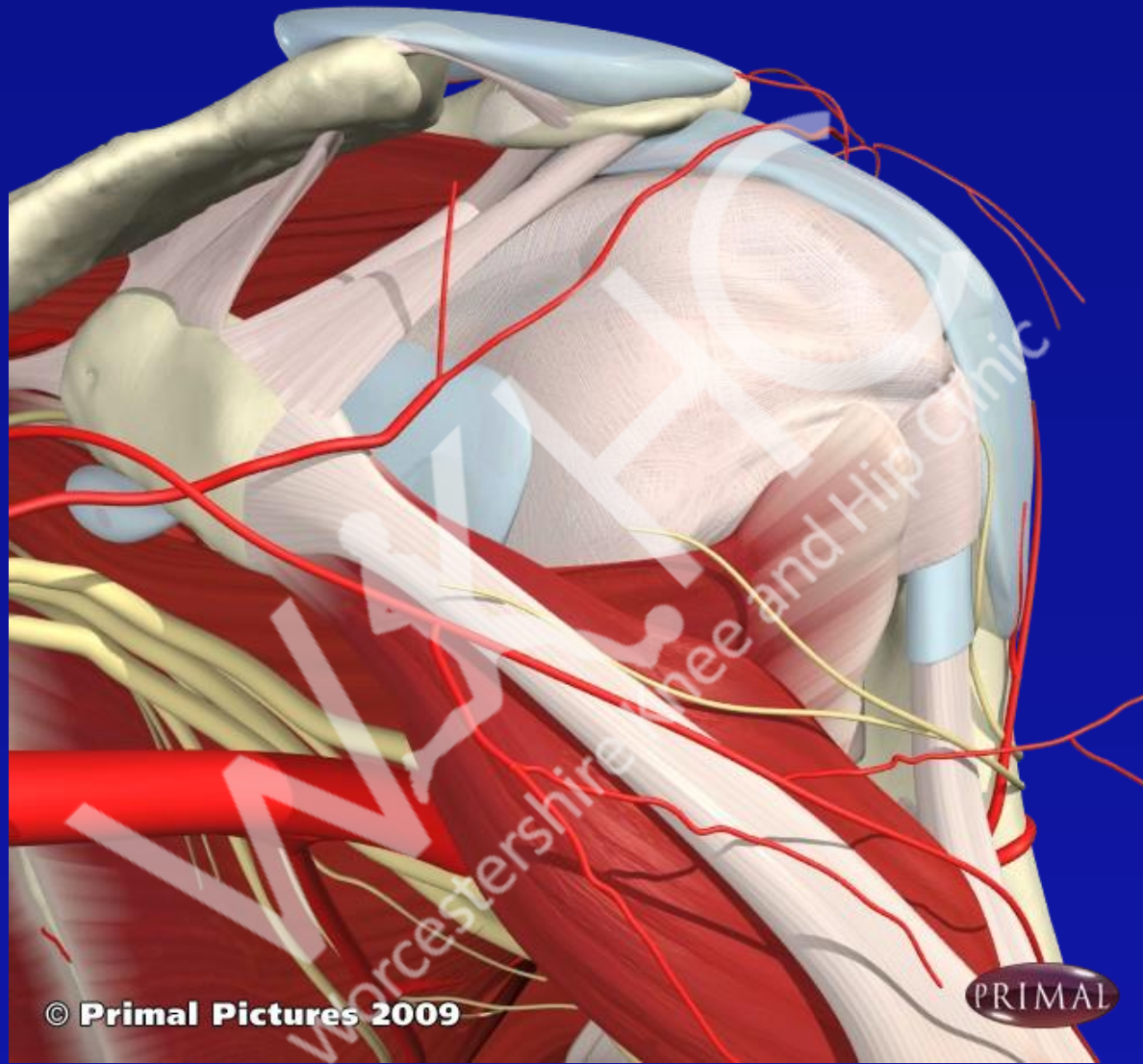
© Primal Pictures 2009

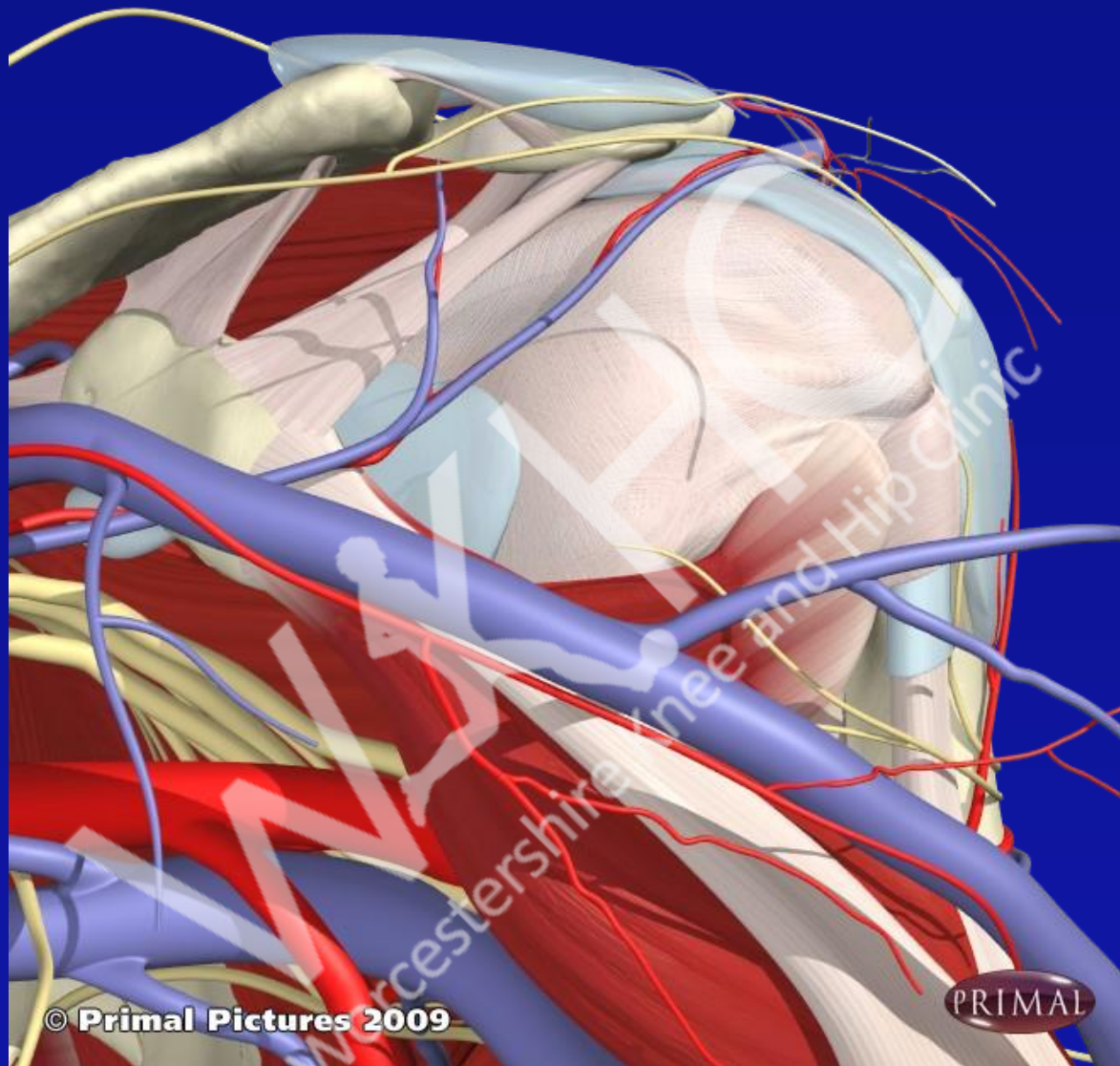




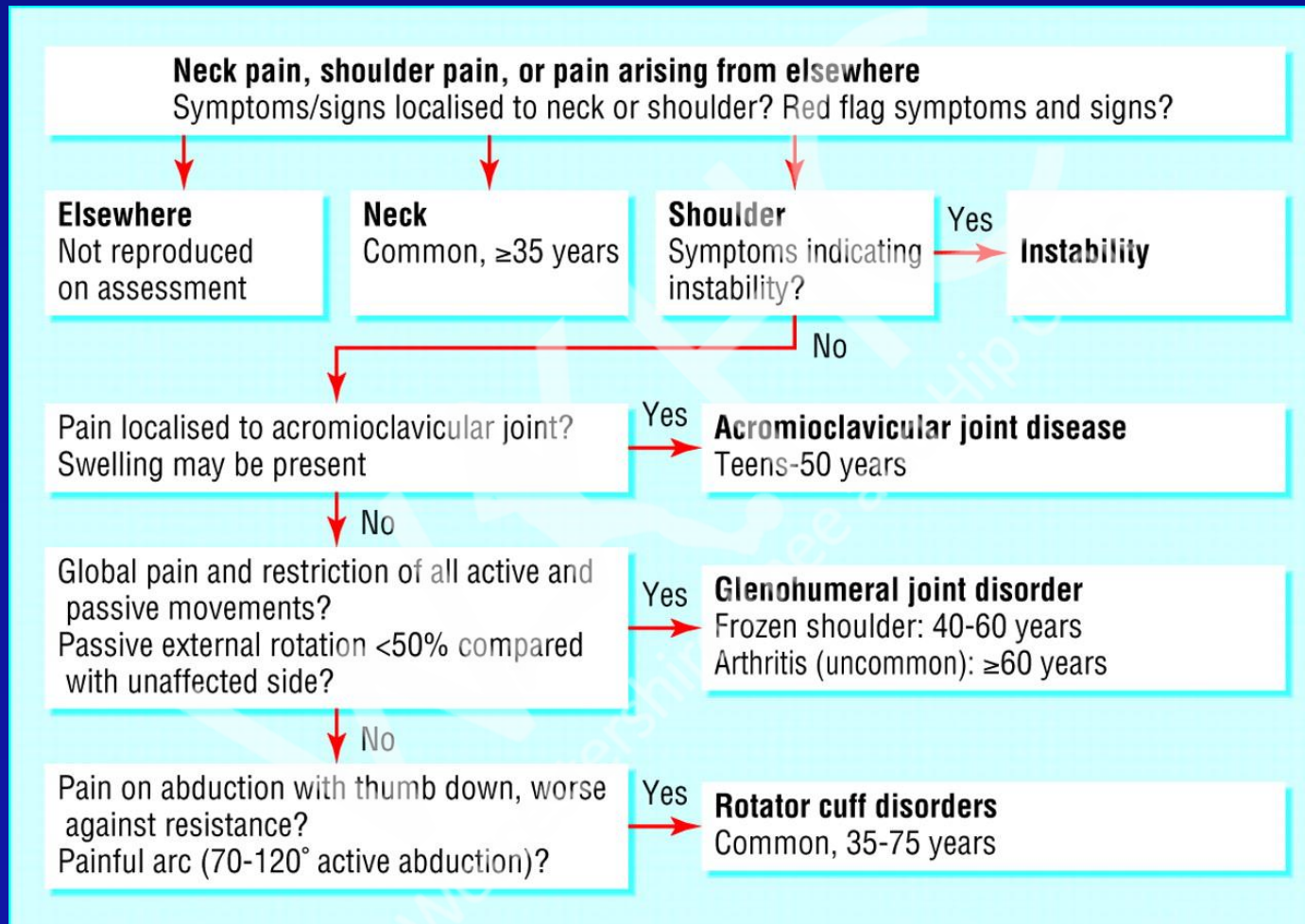
© Primal Pictures 2009







Diagnosis of shoulder problems. Adapted with permission from shoulder pain algorithm:
www.oxfordshoulderandelbowclinic.org.uk



Mitchell, C. et al. BMJ 2005;331:1124-1128

SHOULDER EXAM

- LOOK at skin, contour, compare both sides, muscle atrophy
- FEEL for heat, tenderness
- MOVE
 - Active movement
 - Passive movement

Simple 'rules' for soft tissue problems

- Pain on active movement between 40-80 deg in flexion or abduction will involve cuff
- Pain on active movement, mainly with abduction 40-80 deg likely to be supraspinatus tendonitis
- All of above will have almost normal passive movement
- Pain and loss of movement, active and passive in all planes of movement indicates adhesive capsulitis

Subacromial Impingement

Pain caused by impingement

Supraspinatus tendinitis

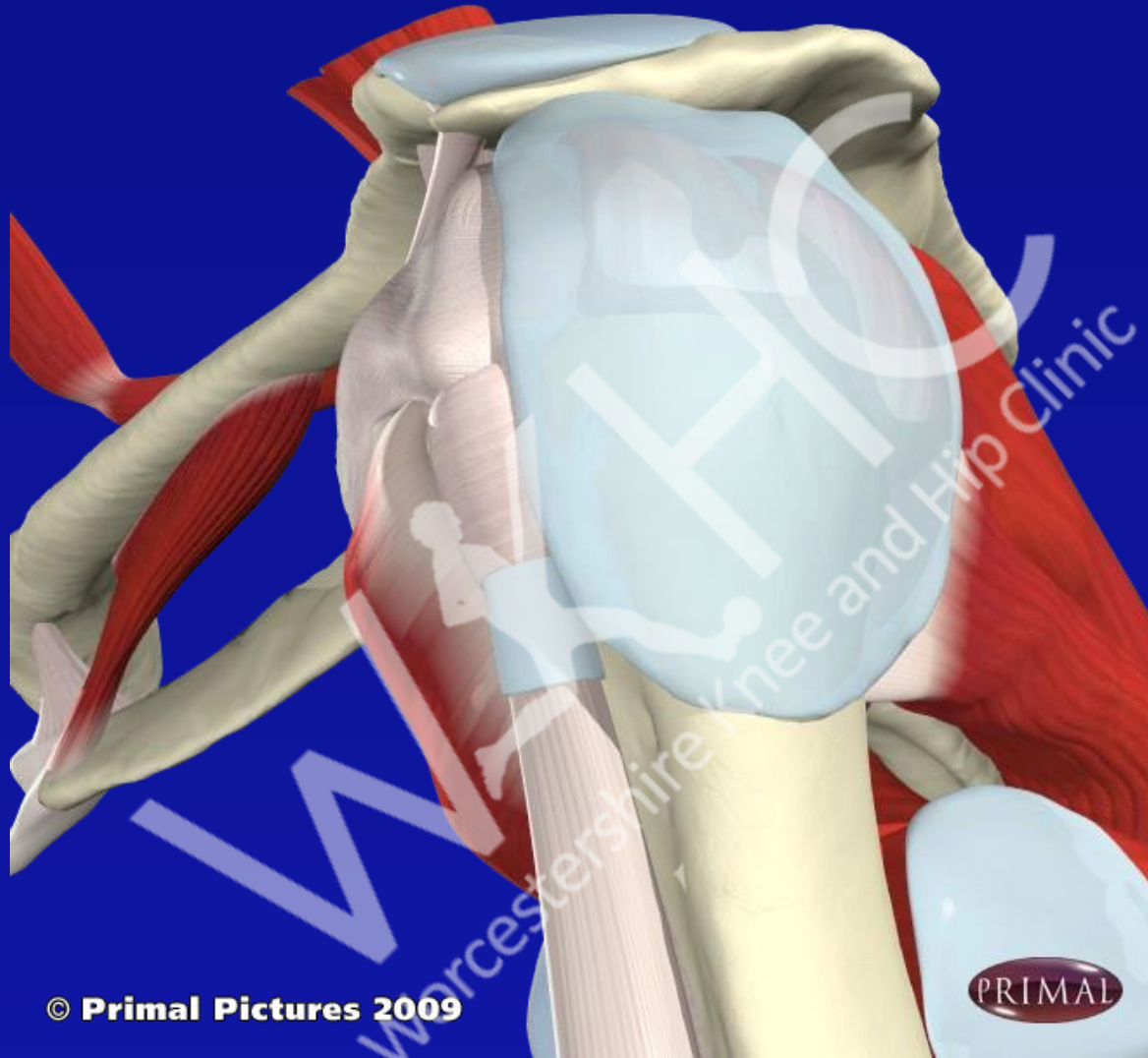
Painful arc of movement

Positive Impingement Test

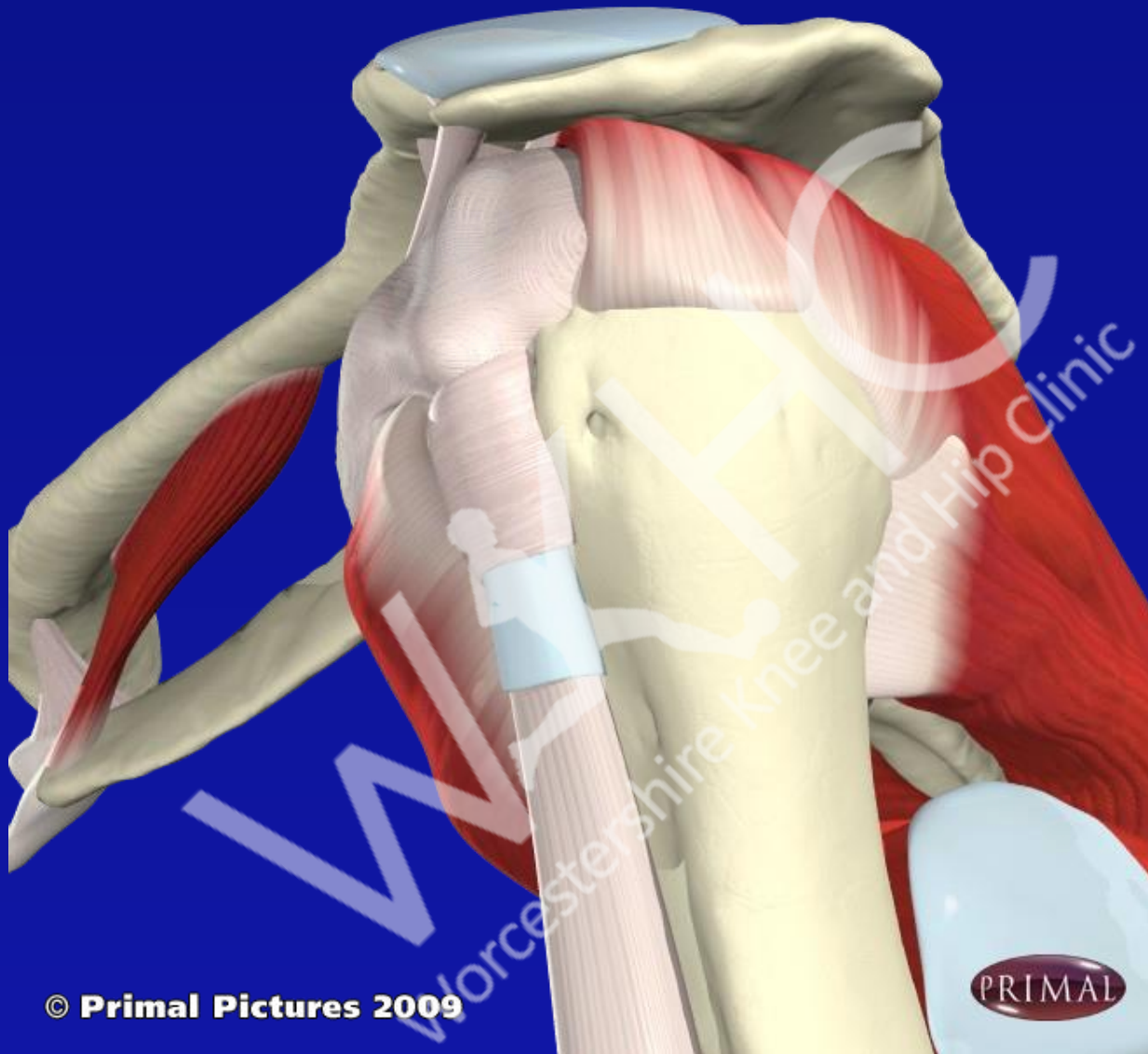
Hawkins

Inject under the acromion process with 40mg
Depomedrone and Lidocaine

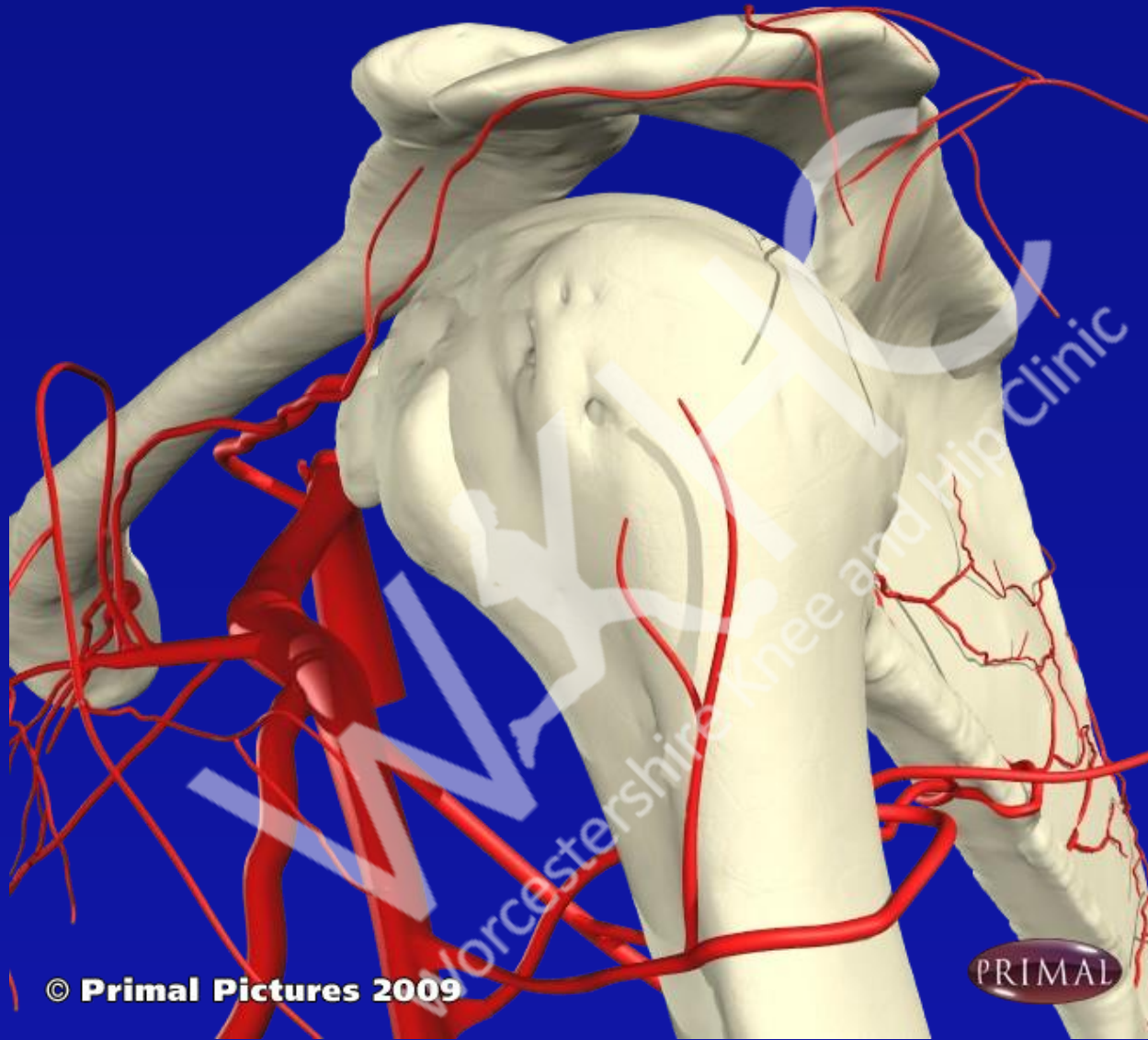




© Primal Pictures 2009

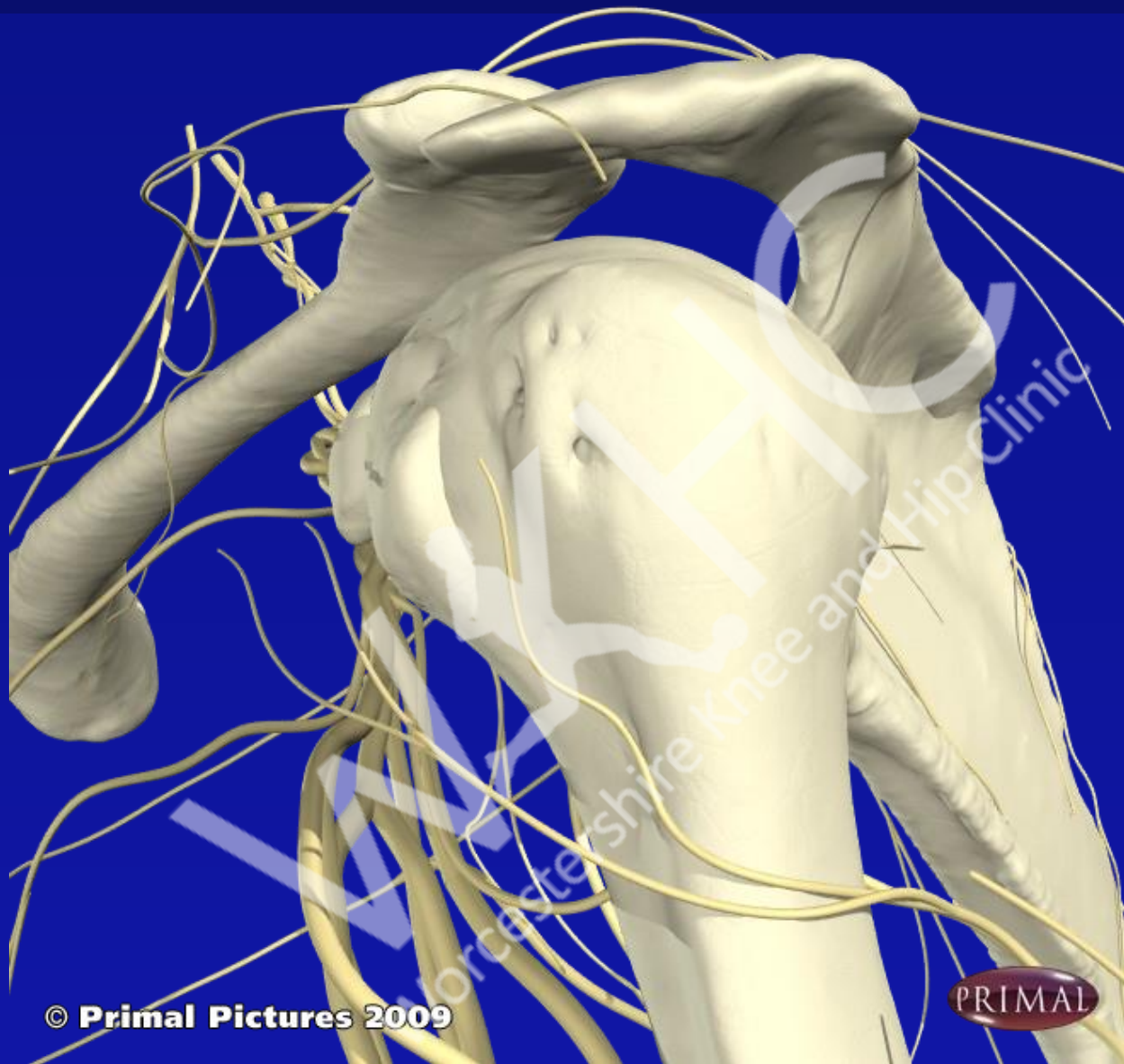


© Primal Pictures 2009



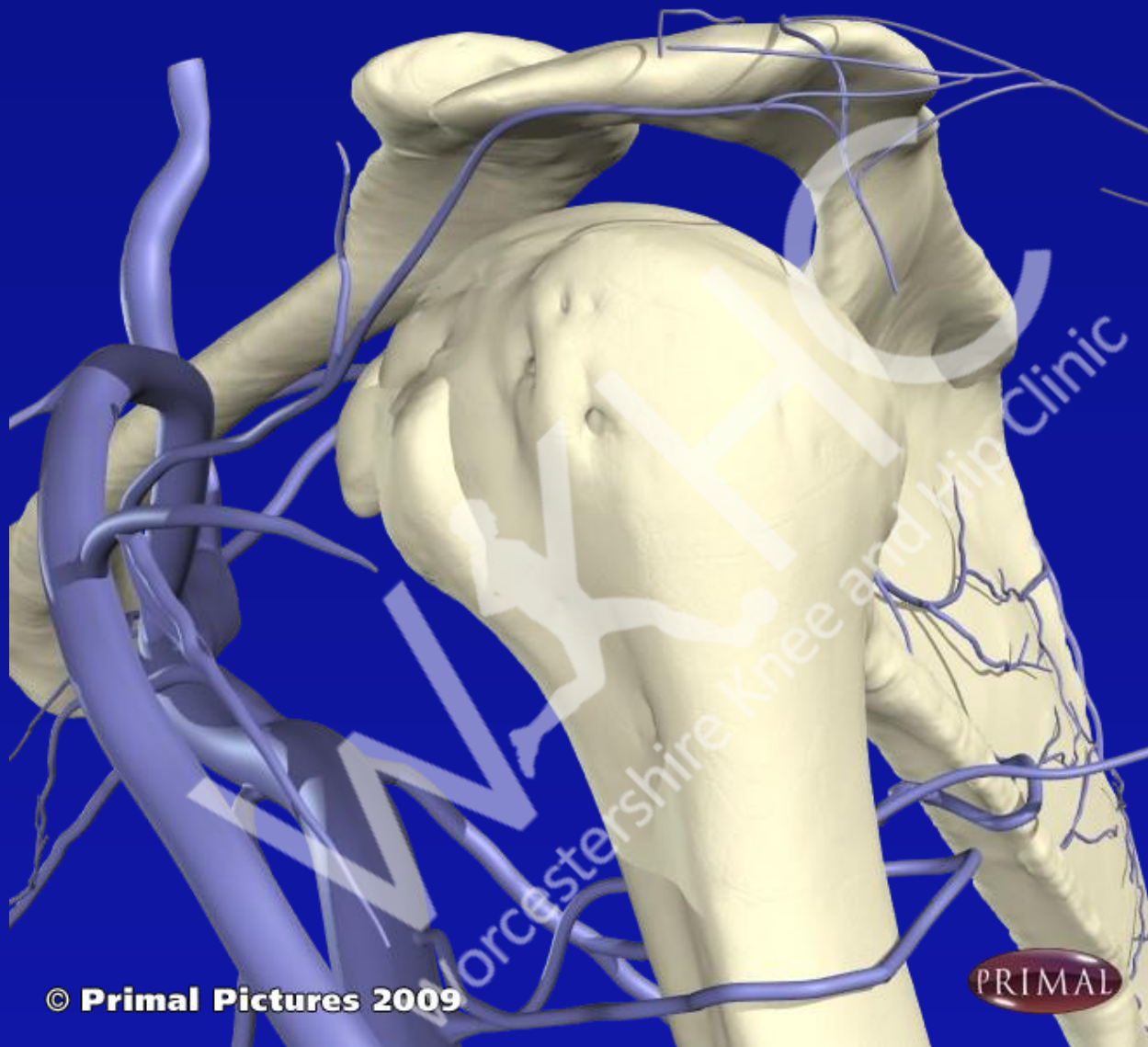
© Primal Pictures 2009





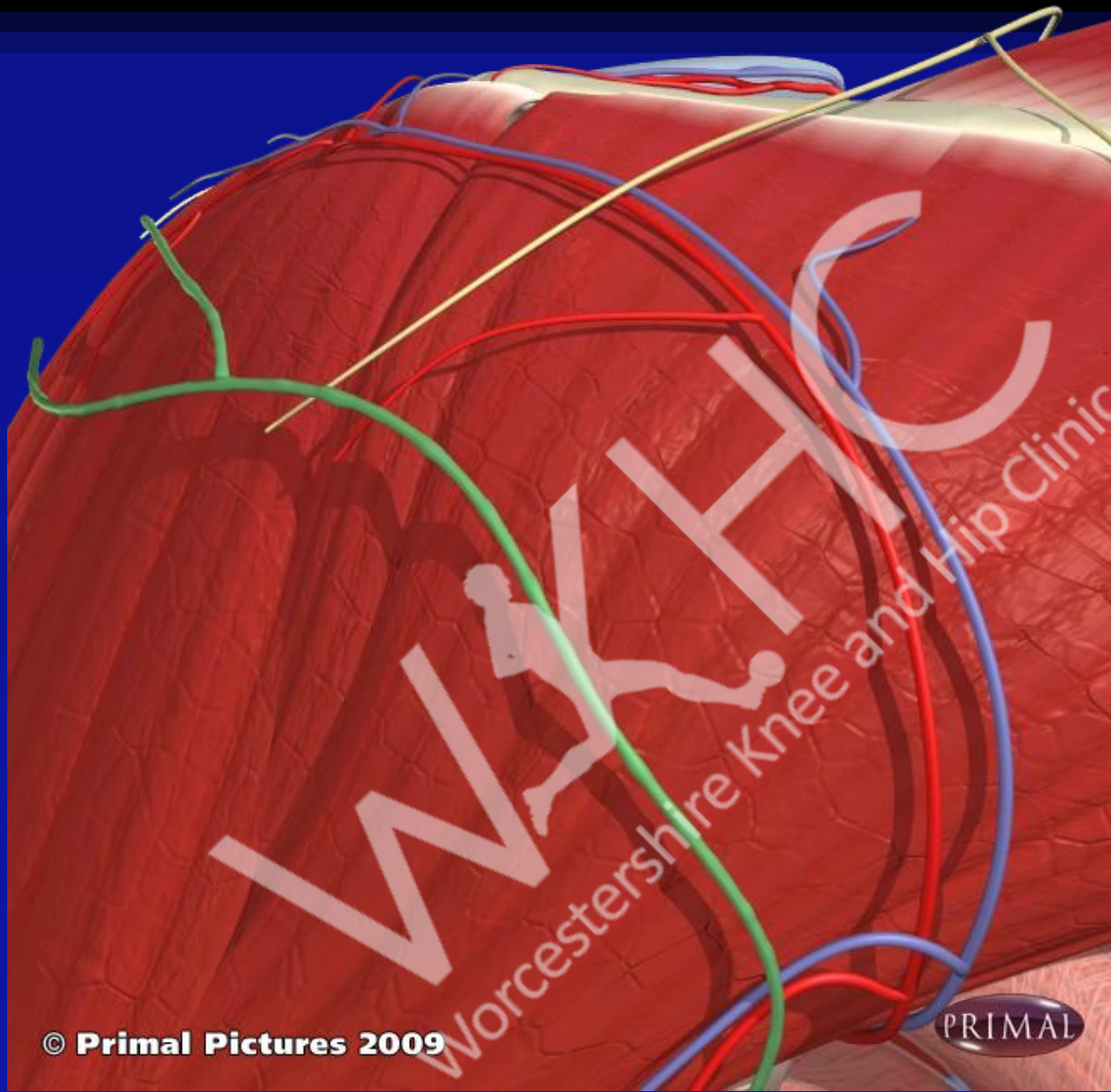
© Primal Pictures 2009

PRIMAL



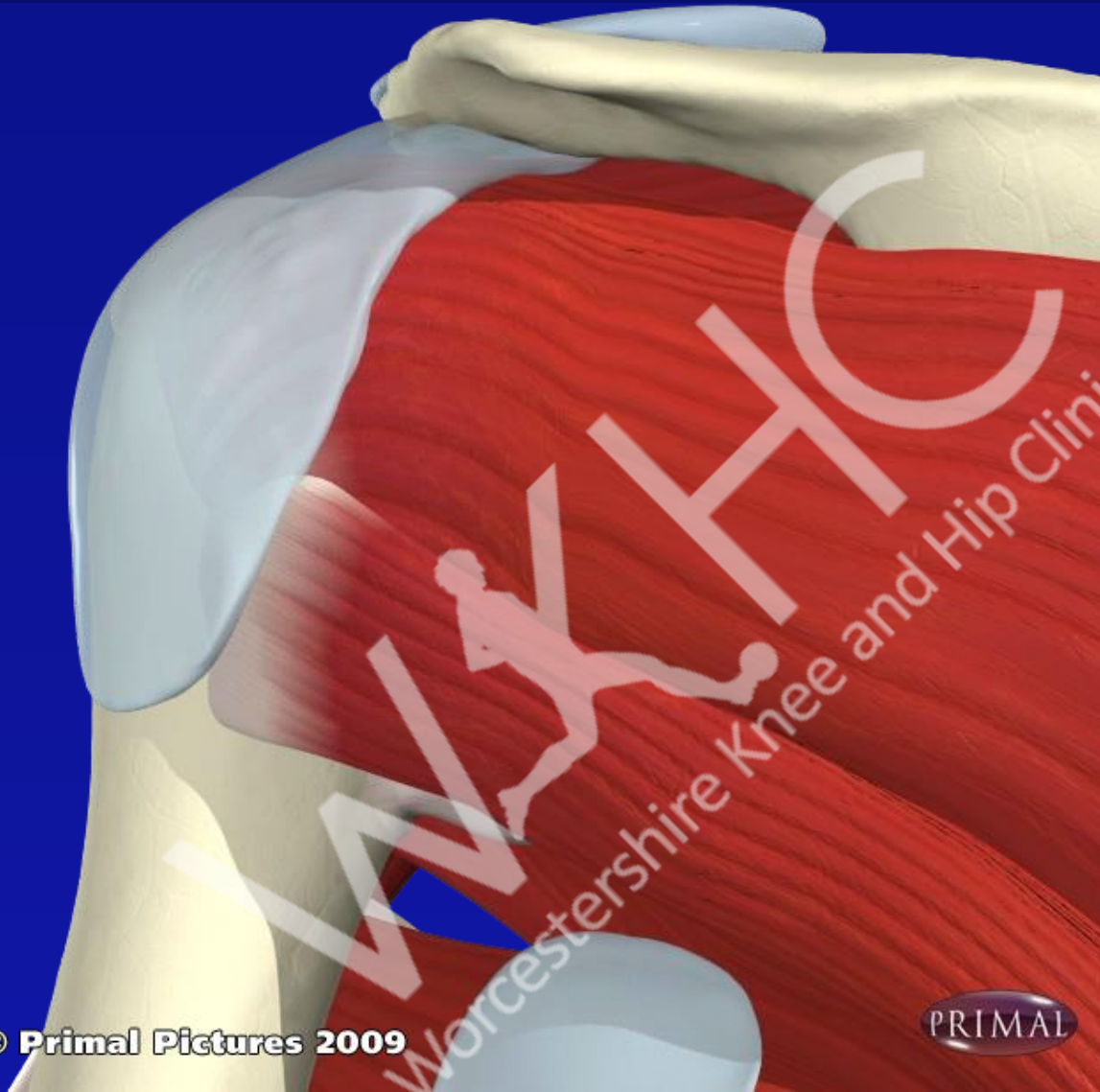
© Primal Pictures 2009





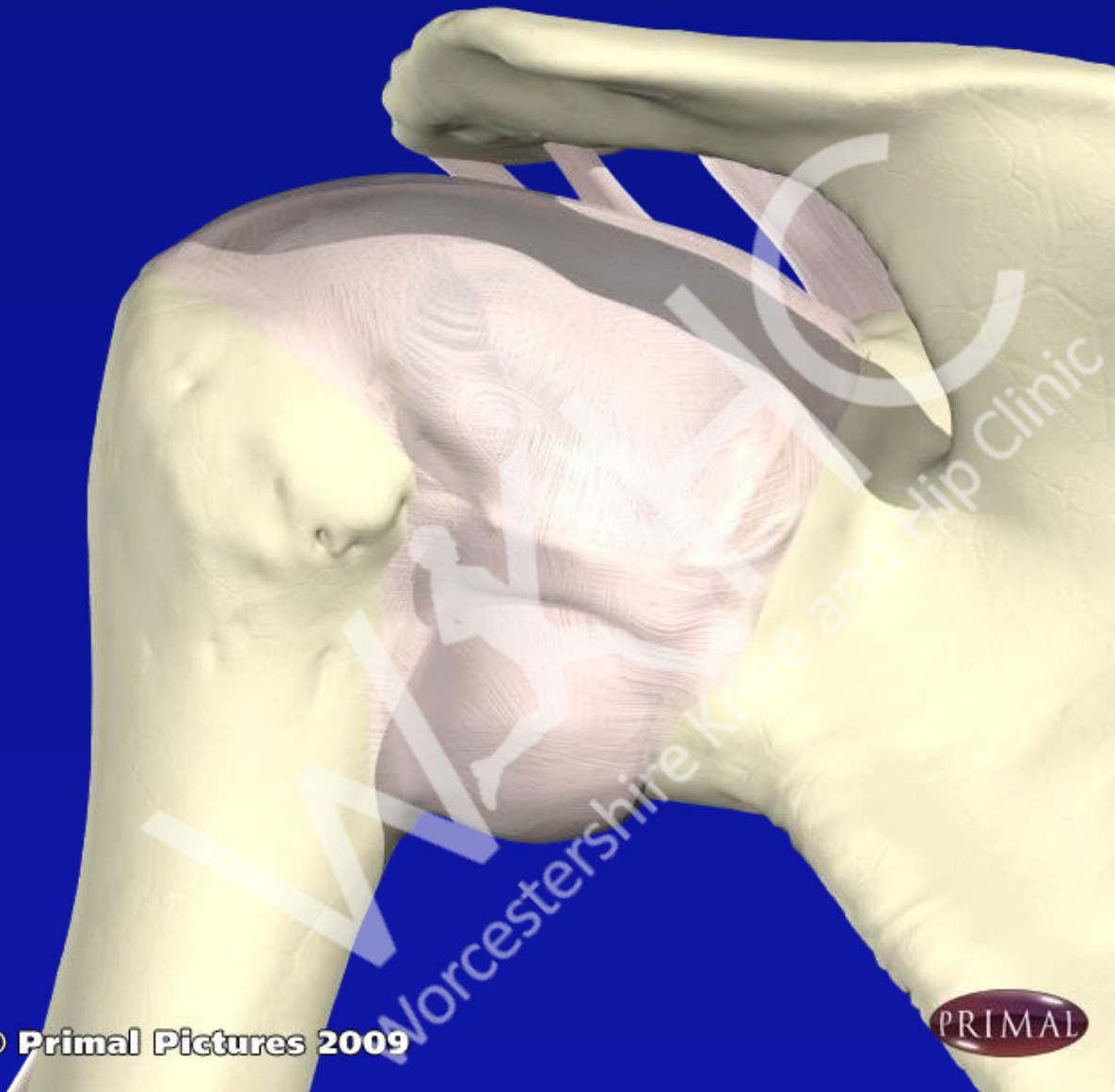
© Primal Pictures 2009

PRIMAL



© Primal Pictures 2009

PRIMAL

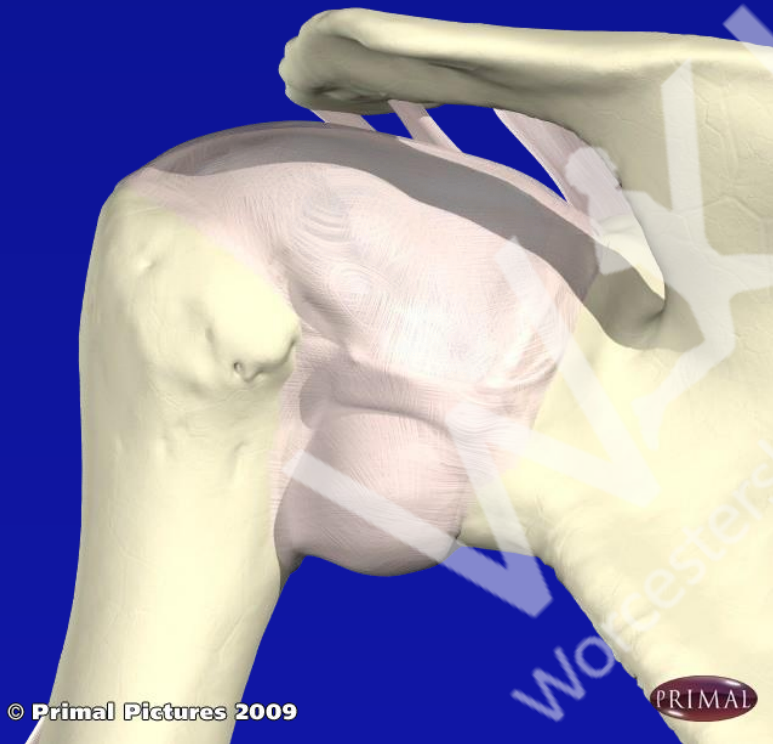


© Primal Pictures 2009

PRIMAL

Subacromial Bursa

- Posterolateral Approach



- Landmarks: Posterolateral border acromion; aim upwards and slightly medially
- Position: Arm hanging by side to distract humerus from acromion
- Needle : green
- Steroid : 40mg
- LA: 5-10 mls total volume

Shoulder pain unresponsive to injection

Exclude other causes:

Breast carcinoma

Pancoast tumour upper lobe lung

Referred from cervical spine

Thoracic outlet syndrome

Referred from viscera:- MI, Pleurisy, Gall bladder, pericarditis

If pathology excluded can help relieve pain with supra scapular nerve block.

Adhesive capsulitis (Frozen shoulder)

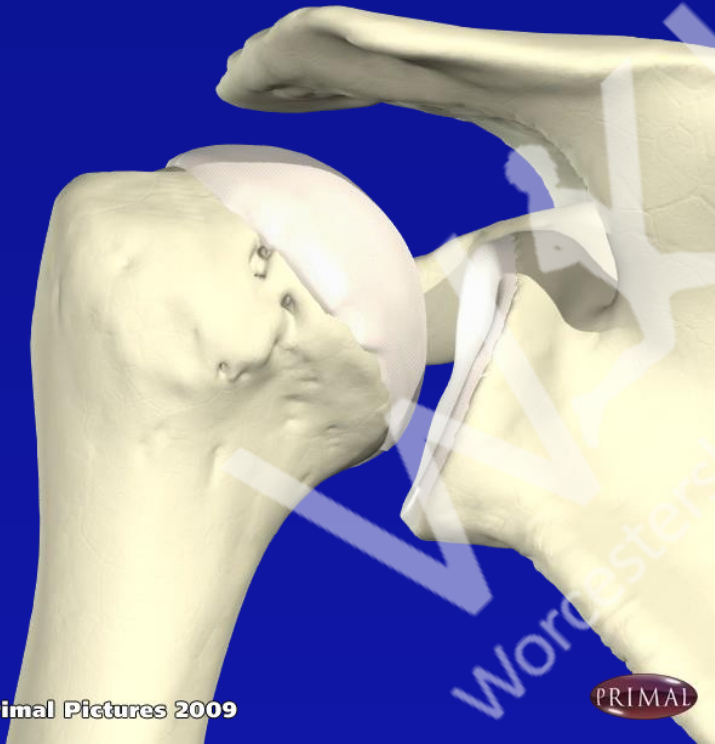
- Capsular thickening and restriction, with low grade inflammation
- Loss or range of movement in all planes both active and passive, particularly rotation
- Pain felt over lateral aspect of arm (C5) often worse at night
- Common in middle aged and elderly and diabetics

Adhesive capsulitis

Course of three injections 6 weeks apart, started as soon as possible after onset of symptoms

3 phases: Painful
Adhesive
Recovery

Glenohumeral joint - posterior approach



© Primal Pictures 2009

- Landmarks: Posterior angle acromion, inject below acromion, obliquely toward coracoid process
- Position: Arm on lap, medially rotated
- Needle: Green
- Steroid: 40mg
- LA: 8-10mls
- Uses: Capsulitis

Glenohumeral joint - anterior approach



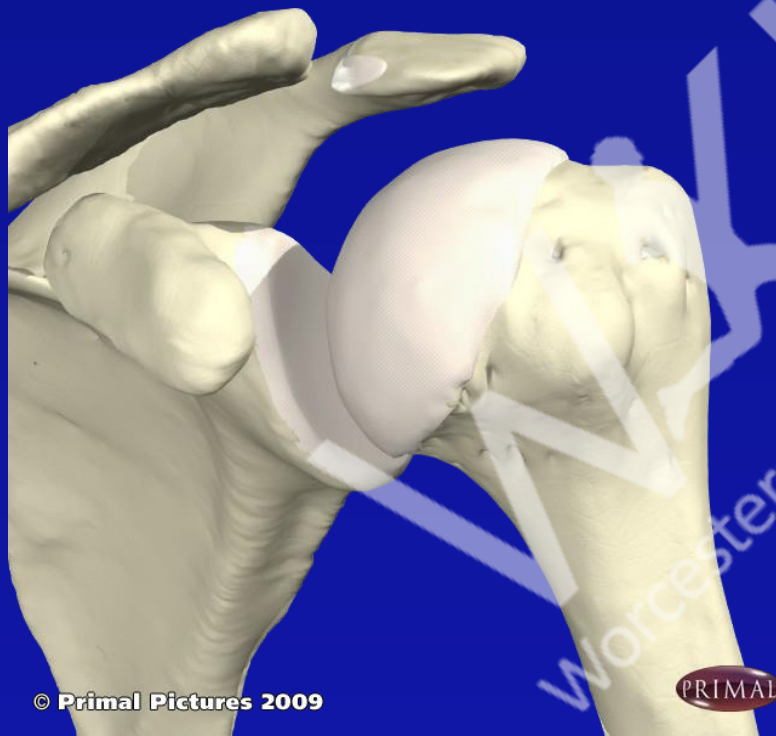© Primal Pictures 2009

- Landmarks: Lateral to coracoid process, medial to humeral head; joint line. Aim posterior
- Position: Arm by side, externally rotated
- Needle: Green
- Steroid : 40mg
- LA: 8-10mls 0.5%
- Uses: Capsulitis

Acromioclavicular joint

- Commonly affected in OA
- More common in manual workers, sports players eg. Rugby players
- Pain over point of shoulder, crepitations on movement
- Pain from approx 80 deg Abd/Flex to end of range
- Pain if touching opposite shoulder

Acromio-clavicular joint



© Primal Pictures 2009

- Landmarks: Follow clavicle laterally to A-C joint. Superior or anterosuperior approach, perpendicular to joint line, angle medially.
- Position: Arm hanging by side
- Needle : Orange
- Steroid : 40mg
- LA: 2ml or none

Bicipital tendonitis

Pain and tenderness in bicipital groove on front of shoulder

Pain in cubital fossa with
Resisted supination and flexion